

# Clinical Case Report: CBCT Guided Implant Surgery Reducing Surgical Morbidity

**Daniel J. Velinsky, DMD**

*Private Practice  
Stuart, Florida*

## Background

The patient, a 62-year-old woman, was referred by a local periodontist for an implant evaluation. It was stated that she was a “difficult patient due to medical complications.” Her stated desire was that “I want to be able to chew.”

## Medical History

The review of systems was negative. The patient was a non-smoker, and used alcohol socially. She was allergic to iodine, and took only hormone replacement medications. She emphasized organic products in her life whenever possible. She stated that she had persistent, recurring yeast infections, which were exacerbated by any antibiotic use. She refused antibiotics for any elective dental treatment.

## Diagnostic Findings

The patient was a healthy woman for her stated age. Her oral hygiene was excellent, and there was no evidence of active periodontal disease. Her cancer screening was negative. The TMJ was quiet with normal range of motion. She was missing teeth Nos. 1 through 4.

## Initial Radiographic Assessment

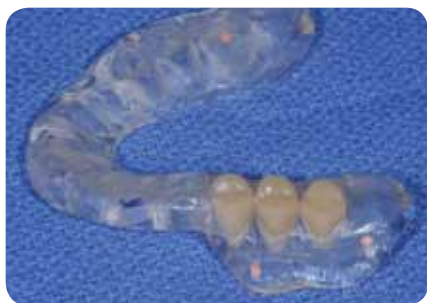Panoramic and periapical radiographs revealed a relatively low maxillary sinus in the area of the prospective implants.

## Initial Actions: December 2002

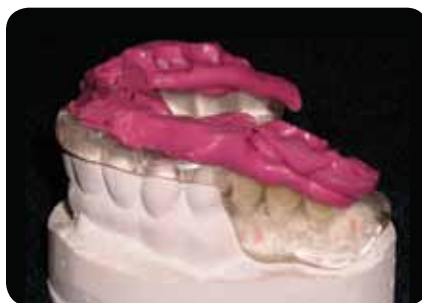The patient was referred to the oral surgeon for an evaluation of the upper right maxilla for implants. With a relatively low sinus, it was determined that the patient would need a unilateral maxillary sinus lift and augmentation. This was discussed with the patient, who subsequently refused treatment due to the need for peri-operative antibiotic coverage for these procedures. As well, she would not accept a removable partial. She opted to initiate no further treatment at this time and desired only a regime of routine maintenance.

## Secondary Presentation: August 2006

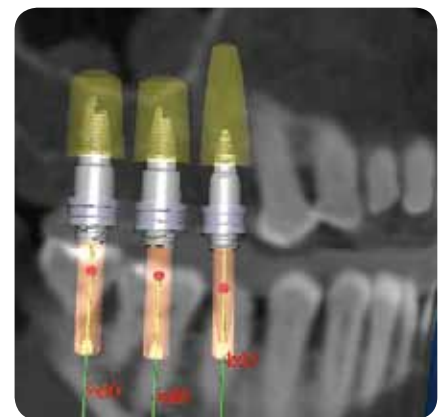
The patient was reexamined with guided implant surgery in mind. She stated that she would accept surgery if it could be



**Figure 1** Scan guide.



**Figure 2** Scan guide with scan bite.



**Figure 3** Procera software diagnostic work-up.

done without antibiotics. A team approach was conceived to include Dr. Daniel J. Velinsky, restorative dentist; Dr. William E. Lippisch, oral surgeon; and Michael Hennessy, CDT, laboratory technician.

## Treatment Goal

The patient's treatment goal was to have teeth in the posterior with which to chew, and she wanted treatment performed without the use of systemic antibiotics. The team's goal included a treatment plan that would result in integrated implants, restored with single, non-splinted crowns, performed with a flapless, minimally invasive guided surgical technique. A one-stage approach without temporization was planned. She agreed to one preoperative antibiotic dose of amoxicillin 2000 mg, and a 5-day course of Peridex oral rinse.

## Scan Guide Construction

An appointment was set with the patient where a polyvinyl siloxane impression was taken of her upper arch, a polyvinyl siloxane bite registration, and an impression of the lower arch. Models were mounted and a wax-up was constructed, giving ideal placement of future implants for teeth Nos. 2, 3, and 4. From this wax-up, a scan guide (Figure 1) was constructed with teeth replacing Nos. 2, 3, and 4, per the Nobel Biocare™ design. Gutta-percha markers were placed in the guide for the dual-scan technique. A flange was designed to hold the prospective future anchor pin. Inspection windows were produced in the guide to ensure its proper and complete seating in the mouth. This is paramount, to ensure a proper relationship of the radiographic guide to the present dentition in the cone beam CT scan (CBCT). This helps to ensure that the laboratory-fabricated surgical guide was properly seated in the mouth during the surgical phase. Prior to the CBCT, a polyvinyl siloxane bite (Figure 2) was taken with the scan guide in place to be used during the CBCT and for subsequent

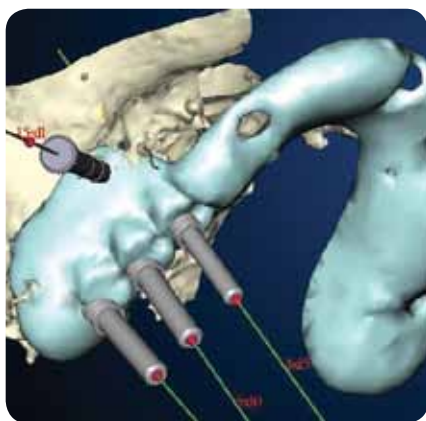
mounting of the case on a semi-adjustable articulator. This would then accurately replicate the surgical plan.

## Surgical Guide Fabrication

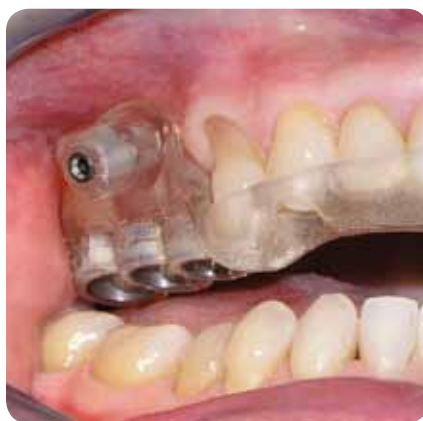A CBCT scan was taken using Nobel Biocare's "double scan" technique. This allowed a marriage of the radiographic scan guide to the patient's Dicom CT information in the Nobel Guide™ Software. A virtual surgery was performed with the Nobel Guide Software (Figure 3 and Figure 4). It was decided that implants could be placed in such a manner as to avoid the sinus lift and augmentation. Working as a team, the final scenario was decided upon. Restorative, surgical, and laboratory issues were discussed and common ground conclusions were decided upon. A Nobel Guide surgical guide was ordered through the software and subsequently produced via stereolithographic rapid prototyping. The guide was tooth-borne with one surgical pin included to aid stabilization (Figure 5). Inspection windows were placed in the guide to ensure full seating during implant surgery.

## Surgery: December 2006

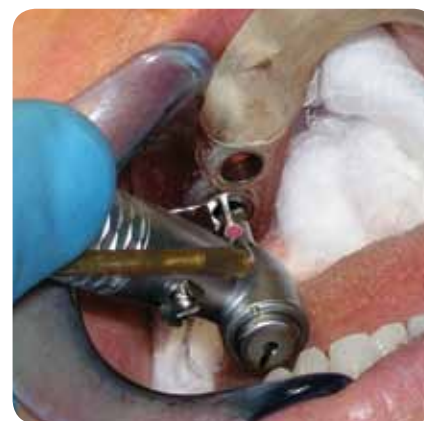The patient was anesthetized using local anesthesia. The Procera™ Surgical Guide was placed, ensuring complete seating using the inspection windows. A determination was made that the patient had adequate attached gingiva and a tissue punch was used through the guide, while it was held in place by finger pressure. The guide was then removed and the tissue plugs were removed with a scalpel and the guide was subsequently replaced. The Nobel Biocare Guided Surgery protocol (Figure 6) was followed, including placement of a stabilization pin and use of a guided template abutment. After all three implants were placed, the guide was removed, any tissue tags present were removed, and healing caps were placed on each implant (Figure 7). Per the plan, no temporary crowns were placed.



**Figure 4** Procera software diagnostic work-up.



**Figure 5** Procera Guide.



**Figure 6** Implant placement using guide.

At 4 months, a standard open-tray impression was taken to produce a mounted master model with a gingival mask. Stock abutments were chosen and modified by Dr. Velinsky and single-unit porcelain veneer crowns were constructed in the laboratory. At a secondary appointment, the healing caps were again removed and the modified abutments were placed and torqued (Figure 8) according to manufacturer's specifications. The crowns were tried in, cemented, and the occlusion adjusted (Figure 9).

## Discussion

This case is not about the design and success of implant placement procedures. At this point in time in dentistry, it can be agreed that implants are successful. This case is about patient management and using the team approach, using a state-of-the-art technique, Nobel Guide, to achieve a patient's desired request. Dentists must not forget that they are treating patients: not teeth, not implants. They must listen to their patient's desires and needs in order to have a successful result. In this instance, conventional implant dentistry may have led to an open procedure with grafting of the sinus. By using a guided technique, adequate length implants were planned and placed, achieving the same goal, but more importantly, respecting the patient's desires.

## Conclusions

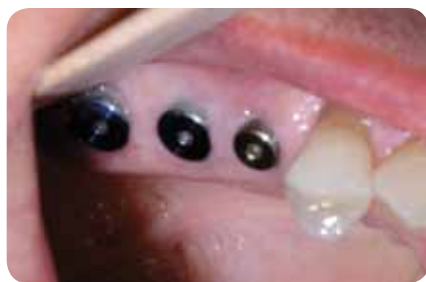By developing a team approach using an oral surgeon, laboratory technician, and restorative dentist, the team was able to design a biologically sound and supportive prosthesis. Using CBCT technology, the team was able to maximize their diagnostic skills in order to idealize the surgical and restorative results. Using minimally invasive techniques, they were able to respect the patient's medical needs by reducing the need for antibiotics and open surgical techniques. By looking at the placement of the implants in the postoperative CBCT (Figure 10), the level of accuracy was achieved with the guided surgery. A 3.5-year follow-up reveals optimal gingival and osseous health (Figure 11 and 12).

## Acknowledgments

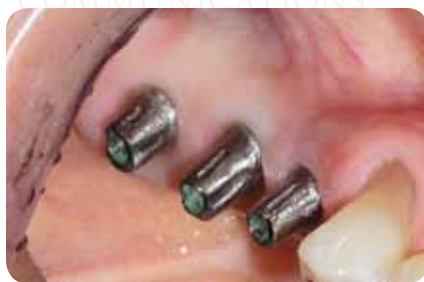Dr. Velinsky would like to thank his surgical team member, Dr. William E. Lippisch, for working in all phases of the case, as well as Michael Hennessy of Hennessy Dental Lab.

## Disclosure

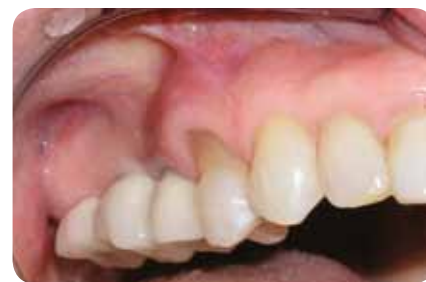Dr. Velinsky does not hold a paid position with Nobel Biocare. He lectures and gives seminars on Team Implant Dentistry for Nobel Biocare.



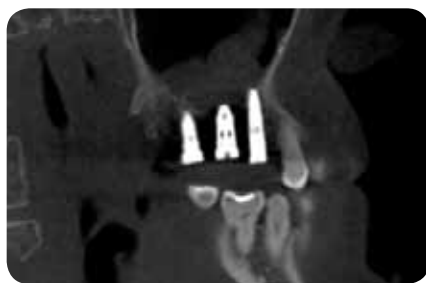
**Figure 7** Healing caps.



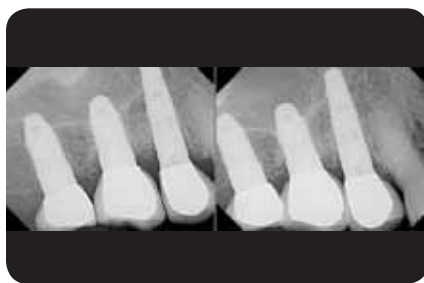**Figure 8** Abutments torqued in place.



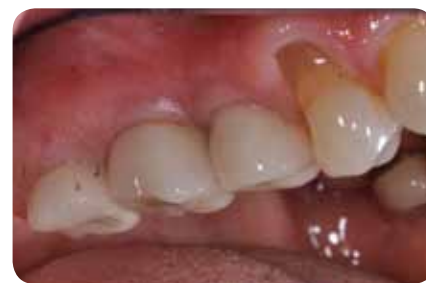**Figure 9** Crowns at time of cementation.



**Figure 10** Final CBCT of placement.



**Figure 11** 3.5-year recall.



**Figure 12** 3.5-year recall.

AEGIS  
COMMUNICATIONS