

One-year results of the intrascleral glaucoma implant

S. Gregory Smith, M.D., John C. Galanis, M.D.

ABSTRACT

This is an initial report from a study to determine the safety and efficacy of an implant placed within the sclera to relieve elevated intraocular pressure (IOP). It describes the first eight patients to receive the implant. Intraocular pressure and pneumotonometry were evaluated preoperatively and postoperatively for one year. In five patients, IOP decreased. Three patients in which the implant was considered a failure because of wound leaks had patch grafts, removal of the implant, or both. The five successful cases have continued to show reduced IOP.

Key Words: facility of outflow, glaucoma, intraocular pressures, intrascleral glaucoma implant, uveal scleral outflow, wound leak

Pasquale and Smith¹ have suggested that aqueous can exit through the sclera in patients having combined phacoemulsification and trabeculectomy. In an attempt to improve the results of glaucoma surgery, a device made of a 70%-water-content hydrogel with a series of 0.1 mm grooves on its inferior side has been designed. The device is 0.2 mm thick, 4.0 mm wide, and 6.0 mm long (Figure 1). It is designed to allow the aqueous to enter the large spaces between scleral fibers and then to be collected by the episcleral venous drainage system.

Since the pressure in the episcleral veins is thought to be 9 mm Hg, placement of the device in the sclera with a watertight scleral closure and a small sclerostomy underneath the device allows the aqueous to exit the anterior chamber and be distributed to the sclera by the channels on the device, which should allow a reduction in intraocular pressure (IOP) and no postoperative hypotony. A filtering bleb should not be needed. Having completed successful trials in animals, we are performing a pilot study, the current results of which are reported here.

MATERIALS AND METHODS

To qualify for the study, patients had to have previous unsuccessful glaucoma surgery, acuity of count-




Fig. 1. (Smith) Intrascleral glaucoma implant composed of 70%-water-content hydrogel.

ing fingers or worse, and an IOP greater than 30 mm Hg for three successive weeks. Intraocular pressure had to be evaluated by the same person using the same tonometer within an hour of the established time for measuring this pressure. External photographs, pneumotonometry, medication history, and di-

From Wills Eye Hospital, Philadelphia, Pennsylvania, and Wilmington, Delaware (Smith), and Southwest Medical Center, St. Louis, Missouri (Galanis).

Dr. Smith has a financial interest in the intrascleral glaucoma implant device.

Reprint requests to S. Gregory Smith, M.D., 1100 Grant Avenue, Wilmington, Delaware 19805.

Table 1. Patient characteristics before placement of intrascleral glaucoma implant.

Patient #	Characteristics
1	Central retinal vein occlusion, rubeosis, status post cryo
2	Aphakic, status post trabeculectomy
3	Status post corneal transplant, intraocular lens exchange, status post trabeculectomy with massive choroidals requiring vitrectomy
4	Status post vitrectomy, corneal transplant herpes simplex keratitis, graft rejection, trabeculectomy with Mitomycin-C
5	Status post central retinal vein, status post trabeculectomy
6	Aphakic, status post trabeculectomy
Second-Stage Patients	
7	Status post alkali burn, status post YAG cyclophotocoagulation \times 5
8	Aphakic, glaucoma, status post trabeculectomy

lated examination were obtained in the week before surgery.

In the first six patients, a fornix-based flap was raised and cautery was used to obtain hemostasis. The device was placed on the eye, straddling the limbus. A one-third depth scleral flap was made with a diamond knife, outlining the exact dimensions of the device. Then the flap was raised into clear cornea. The device was placed within the flap and the flap bed was undermined, if necessary, so the device would fit into the bed created without tension. Once this was established, a 1 \times 2 mm block of corneal and scleral tissue was excised at the limbus. A peripheral iridectomy

was not performed unless there was prolapse of the iris into the surgical wound after closure of the sclera. Once the block of tissue had been removed, the device was placed in the bed, with the grooved side facing posterior, and the sclera was closed with eight to ten 10-0 nylon sutures. These were tied and trimmed and the conjunctiva was closed with two 6-0 plain sutures.

In two additional patients operated on in a second stage of the pilot study, a limbal-based conjunctival flap was made. Otherwise, the surgical procedure was the same in all eight patients.

Postoperatively, patients were seen on the first day, at one week, and then monthly for three months. After three months, they were seen at three-month intervals until one year after surgery. At the three-month visit, pneumotometry, slitlamp photography, fundus examination, and gonioscopic photographs were evaluated. Intraocular pressure was measured in the same room, at the same time of day, by the same examiner as preoperatively.

RESULTS

Table 1 summarizes the preoperative characteristics of the patients. Table 2 shows the preoperative and postoperative IOPs and Table 3, the pneumotometry measurements preoperatively and at three months postoperatively.

At one week and three months, no patient had a filtering bleb (Figures 2 and 3). At six months, the sclera above the implant in patient 1 became clear and the conjunctiva elevated, although no thinning of the sclera occurred (Figure 4). An increase in IOP was associated with the development of this bleb-like appearance. In the three patients in whom there was a wound leak, hypotony was noted. In patient 2, IOP returned to 17 mm Hg at three weeks with no medications from a previous level of 38 mm Hg, and the

Table 2. Preoperative and postoperative IOP.

Patient	Preoperative IOP	Postoperative IOP					
		1 Day	1 Week	3 Months	6 Months	9 Months	1 Year
1	72	49	28	10	34	22	32
2	37	28	11	Patch graft	Device removed at 6 months		
3	30	48	42	22	23	27	21
4	30	10	32	Patch graft		—	—
5	30	26	21	20	17	21	19
6	33	4	5	Patch graft		—	—
Second, Stage							
7	42	17	17	19	17	15	—
8	37	5	15	17	18	—	—

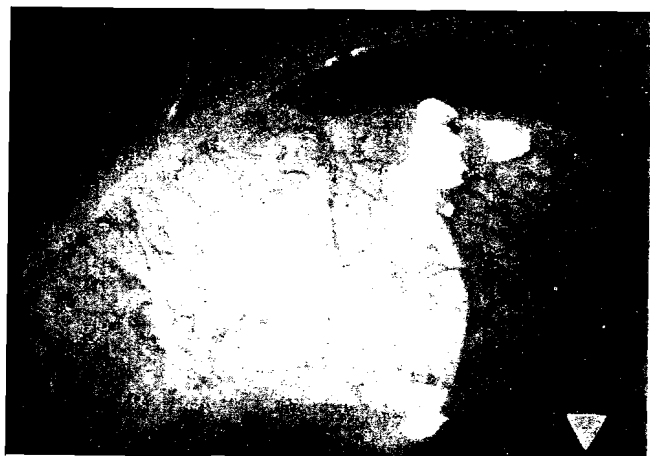

Fig. 2. (Smith) Patient 1 at one week postoperatively.

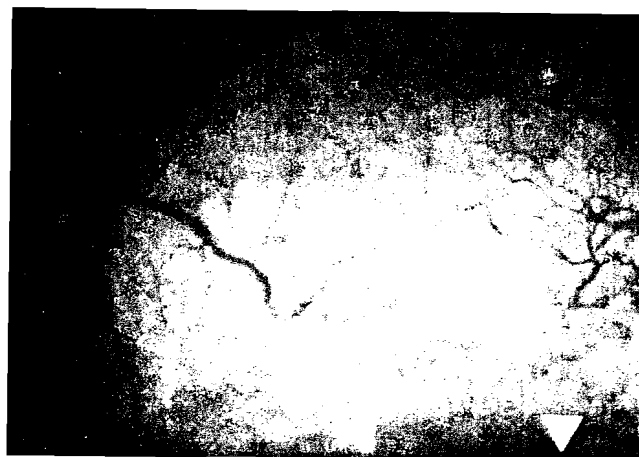


Fig. 3. (Smith) Patient 1 at three months postoperatively. No filtering bleb is present.




Fig. 4. (Smith) Patient 1 at six months postoperatively. The patient has developed a filtering bleb over the implant.

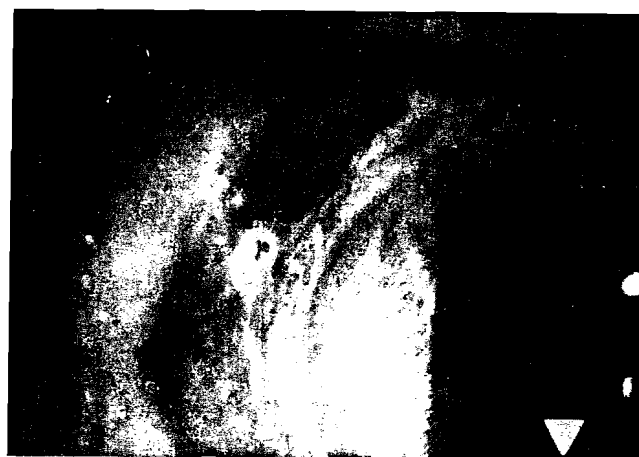

Fig. 5. (Smith) Intrascleral hematoma. Blood is dissecting into the lamellar dissection in the cornea surrounding the implant.

patient developed a wound leak from a suture barb protruding through the conjunctiva. Multiple procedures to close this were used, including a simple purse-string closure, small conjunctival flaps, and, finally, a scleral patch graft. Since leakage continued after the graft, it was removed, together with the implant, and a lamellar corneal transplant was performed. The patient's eye has continued to leak and appears to have developed epithelial ingrowth because of the long period with a nonsealed wound. Two other patients who had a wound leak in the early postoperative period had a scleral patch graft which stopped the leakage. All three implants were considered failures.

Another complication associated with the device was an intrascleral hematoma, which occurred in one patient (Figures 5 and 6). This was managed by observation and medical treatment of the elevated IOP. The patient has done well, with no infections and no subluxations into the anterior chamber. There were no flat anterior chambers.

DISCUSSION

When successfully implanted, as it was in five of the eight patients reported, the intrascleral glaucoma

Table 3. Pneumotonometric readings preoperatively and three months after surgery.

Patient	Mean Facility of Outflow ($\mu\text{l}/\text{min}$) Preoperatively	Mean Facility of Outflow ($\mu\text{l}/\text{min}$) 3 months Postoperatively
1	Off scale	0.32 (0.80)*
2	Off scale	Patch graft
3	Off scale	0.17 (0.90)*
4	0.11 (7.20)*	Patch graft
5	0.39 (2.70)*	0.27 (1.10)*
6	0.02 (3.10)*	Patch graft

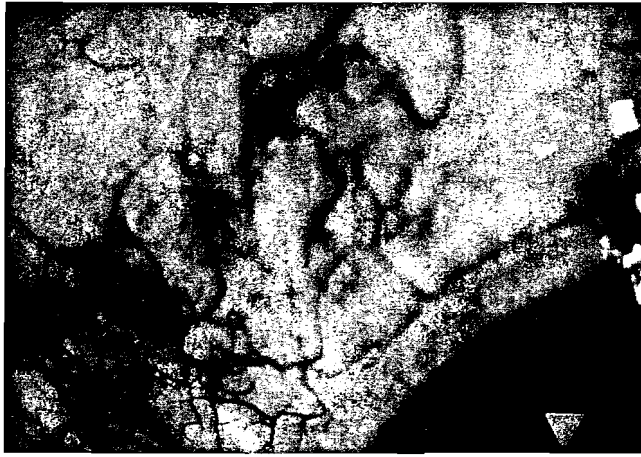


Fig. 6. (Smith) Patient in Figure 5 three months postoperatively. The blood has completely resolved and the pressure is controlled without medication.

implant reduced IOP and increased outflow in eyes that had had unsuccessful glaucoma surgery. No hypotony was noted with this device unless a wound leak was present. The IOP change was gradual over a one- to two-week period.

Theoretically, the intrascleral implant allows fluid to escape into the coarsely woven sclera, which has large openings of approximately $10 \mu\text{m} \times 2 \mu\text{m}$.² Once in the sclera, the fluid is collected in the venous drainage system and returned to the circulation. Al-

though the present pilot study cannot prove this theory, findings thus far offer some support for it. In the patient who developed a filtering-bleb-like appearance, the associated rise in pressure may have occurred because the aqueous could not escape into the sclera due to fibrovascular ingrowth of the scleral wound.

The difficulties with wound leaks in the first stage of the study indicate that the surgery should be performed with a limbal-based flap. In the second study stage, this flap has been used in two of six planned surgeries; both patients are doing well. It is apparently unnecessary to close the sclera watertight during the initial implantation. If a wound leak occurs after implantation, we recommend that the implant be removed as it is difficult to control the wound leak once it has occurred. Techniques of the surgical procedure are being refined as more patients are entered in the study. These patients will continue to be observed, and trial of the device in a multicenter group study is planned.

REFERENCES

1. Pasquale LR, Smith SG. Surgical outcome of phacemulsification combined with the Pearce trabeculectomy in patients with glaucoma. *J Cataract Refract Surg* 1992; 18:301-305
2. Komai Y, Ushiki T. The three-dimensional organization of collagen fibrils in the human cornea and sclera. *Invest Ophthalmol Vis Sci* 1991; 32:2244-2258