

articles

Safety and efficacy of 2% methylcellulose in cat and monkey cataract-implant surgery

S. Gregory Smith, M.D. Stewart Hazel, D.V.M.
Richard L. Lindstrom, M.D. Debra Skelnik, B.S.
Richard A. Miller, M.D. Patricia Williams, C.O.T.
Elizabeth Mindrup, B.S.
Minneapolis, Minnesota

ABSTRACT

We evaluated the safety and efficacy of 2% methylcellulose as an adjunct for cataract extraction with implantation in cat and monkey models. When used intraoperatively, methylcellulose reduced the iridovitreal bulge during surgery. No significant increase in clinical inflammation occurred nor was there statistically significant intraocular pressure elevation at 24 hours, 7 days, or 90 days. In the cat model, the central corneal thickness increased at day seven in both control and methylcellulose eyes; this thickness persisted to 90 days. The endothelial cell loss decreased significantly at day 90 in methylcellulose eyes. In the monkey model, no statistically significant increase in corneal thickness occurred in control or methylcellulose eyes at day seven. The endothelial cell loss was greater than in the cat model in both control and methylcellulose eyes; there was no statistically significant difference between the two.

Two percent methylcellulose was safe in both the cat and monkey models. It facilitated surgery in both models and reduced the endothelial cell loss in the cat eye.

Key Words: cataract-implant surgery, methylcellulose, pachometry, specular microscopy, viscoelastic, viscosurgery

The importance of minimizing contact between a polymethylmethacrylate intraocular lens (IOL) and the corneal endothelium is well established.¹ Several techniques to minimize intraoperative endothelial cell damage have been developed, including the use of viscoelastic surgical adjuncts such as sodium hyaluronate² and chondroitin sulfate.³

In this study we evaluated the safety and efficacy of 2% methylcellulose as a viscosurgical adjunct in cataract-lens implant surgery using cat and monkey models.

MATERIALS AND METHODS

Three surgeons performed planned extracapsular cataract extraction or Kelman phacoemulsification followed by posterior chamber IOL implantation on both eyes of 31 cats and five monkeys. A viscoelastic substance, 2% methylcellulose, was used in the left eye of each animal intraoperatively. The right eye served as a control, undergoing the same type of surgery by the same surgeon but without methylcellulose.

Five effects were examined in each case. First, the ease of surgery was subjectively evaluated by the

This study was supported in part by a research grant from Barnes-Hind Pharmaceuticals, Inc., Sunnyvale, California.

From the Department of Ophthalmology, University of Minnesota, Minneapolis, Minnesota.

Send reprint requests to S. Gregory Smith, M.D., 2323 Pennsylvania Avenue, Wilmington, Delaware 19806.

operating surgeon and graded as methylcellulose eye easier or control eye easier. In particular, the presence and severity of iridovitreous bulge was evaluated.

Second, postoperative clinical inflammation was graded by external examination and slitlamp evaluation at 24 hours, 7 days, and 90 days. Inflammation was graded as minimal, mild, moderate, or severe in each eye.

Third, the intraocular pressure (IOP) was measured in each eye before surgery, at 24 hours, 7 days, and 90 days using the Digilab appplanation pneumotonometer.

Fourth, central corneal thickness was measured preoperatively and at day seven and 90 with the Product Research Organization contact specular microscope. Three readings were taken in each eye and averaged.

Finally, the central corneal endothelial cell count was determined preoperatively and at 90 days with the Product Research Organization contact specular microscope. Three central corneal photomicrographs were counted in each case and the average count used for comparison. Endothelial cell counts were performed in a masked fashion.

Thirty of the surgical cases were performed by one surgeon, five by a second surgeon, and one by the third surgeon. In each case, both eyes were operated on by the same surgeon using the identical technique.

Phacoemulsification in the posterior chamber was performed on 13 cats. Planned extracapsular cataract extraction with nucleus expression was performed on 18 cats. In all cases the cortex was removed with a Cavitron 7007A machine.

Anesthesia in the cats was attained with subcutaneous acepromazine and atropine followed 20 minutes later by intramuscular ketamine. Specular microscopy was performed and corneal thickness and IOP were measured. The procedure in each eye was identical except that in the experimental eye methylcellulose was injected into the anterior chamber before performing the anterior capsulectomy and before IOL implantation. Since the cat eye is larger than the human eye, the haptics on the posterior chamber lens were increased to 19 mm. After inserting the IOL, the wound was closed with a running 10-0 nylon or 10-0 polypropylene suture. The methylcellulose was aspirated from the eye and replaced with balanced salt solution using the irrigation/aspiration handpiece of the Cavitron unit. Subconjunctival injections of 1 mm betamethasone sodium phosphate and betamethasone acetate (Celestone[®] Soluspan[®]) (6 mg/cc) and 1 mm of gentamycin sulfate (40 mg/cc) were given.

The monkeys were operated on in an identical fashion following anesthesia with intramuscular ketamine and intravenous pentothal. All monkeys had posterior chamber phacoemulsification with placement of a 13-mm uniplanar posterior chamber lens. Methylcellulose was used as in the cat eyes.

Results were evaluated for statistical significance using Student's *t* distribution for continuous variables.

RESULTS

Surgery was performed on 31 cats and five monkeys. Four cats did not complete the 90-day study: One cat died one day postoperatively, one developed endophthalmitis and was sacrificed at four weeks, one died during anesthesia, and one developed an unusual exposure keratopathy. All five monkeys completed the study. This left 27 cats and five monkeys in the analytical study group. Six cats were sacrificed at one week and the remaining 21 cats were sacrificed at three months. All monkeys were sacrificed at three months.

Facility of Surgery

In both cat and monkey models, each surgeon graded surgery to be easier in the methylcellulose eye. Less iridovitreous bulge during phacoemulsification and planned extracapsular cataract extraction and increased ease of posterior chamber lens implantation were noted in all cases. The only disadvantage of the 2% methylcellulose noted by any surgeon intraoperatively was an accumulation of small air bubbles suspended in the methylcellulose in the anterior chamber during phacoemulsification in some eyes.

Clinical Inflammation

Only mild clinical inflammation was noted in any postoperative eye except for the one that developed endophthalmitis at four weeks. No clinically apparent asymmetry in inflammation was noted between methylcellulose and control eyes. Inflammation gradually decreased to a minimum grade at 90 days. Many eyes developed a pupil capture of the IOL optic, which increased iris-IOL contact. In these eyes a hyperemia of the iris was noted in a similar pattern in experimental and control eyes.

Intraocular Pressure

Intraocular pressure readings in control and methylcellulose eyes are shown in Figures 1 and 2. The initial IOP in the cat eyes was measured following ketamine anesthesia and is artificially elevated. No statistically significant difference was noted in cat or monkey eyes at 1, 7, or 90 days postoperatively. No IOL readings were taken before 24 hours postoperatively.

Corneal Thickness

The results of corneal thickness measurements in the cat model for control and methylcellulose eyes are shown in Figure 3. Corneal thickness was increased at day seven and day 90 in both control and methylcellulose eyes. However, there was no statistically significant difference between the two groups.

In the monkey eyes, corneal thickness measurements were taken preoperatively and at day 90 (Figure 4). There was no statistically significant increase in

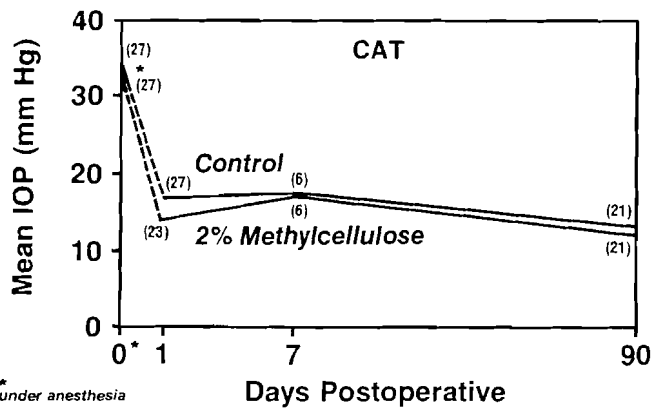


Fig. 1. (Smith) Intraocular pressure in cats operated on with and without 2% methylcellulose. Initial IOP was artificially elevated by ketamine anesthesia. No statistically significant difference between control and methylcellulose eyes was found.

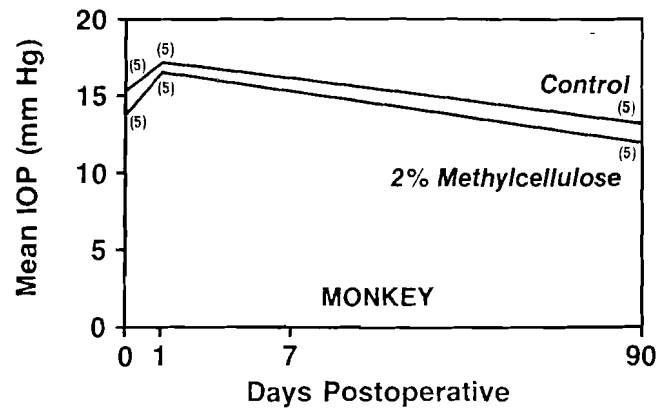


Fig. 2. (Smith) Intraocular pressure in monkeys operated on with and without 2% methylcellulose. No statistically significant difference between control and methylcellulose eyes was found.

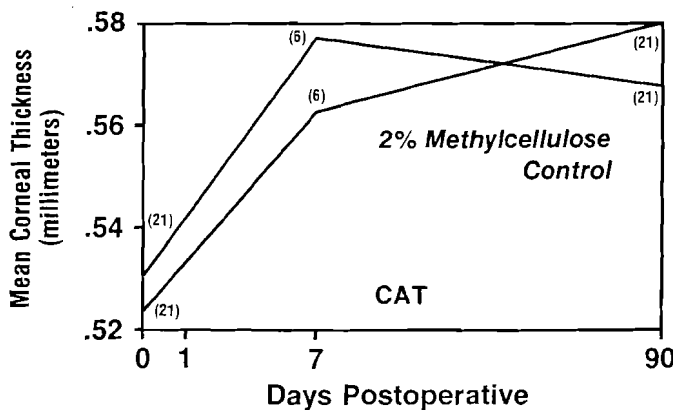


Fig. 3. (Smith) Corneal thickness in cats operated on with and without 2% methylcellulose. No statistically significant difference between control and methylcellulose eyes was found.

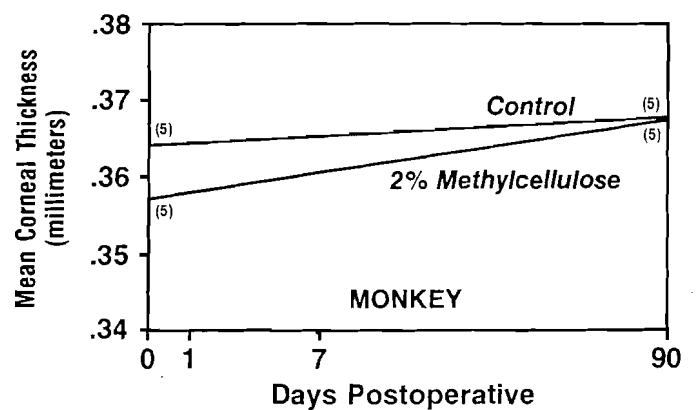


Fig. 4. (Smith) Corneal thickness in monkeys operated on with and without 2% methylcellulose. No statistically significant difference between control and methylcellulose eyes was found.

corneal thickness between control and methylcellulose eyes.

Endothelial Cell Count

Endothelial cell counts were performed in 21 cats and five monkeys (Table 1). In the cat model, the control eyes demonstrated a 17.8% mean endothelial cell loss and the methylcellulose eyes, a 10.7% cell loss. This difference in endothelial cell loss was statistically significant ($P < 0.01$). Methylcellulose therefore provided a statistically significant protective effect on the corneal endothelium in the cat model. This protective effect was noted by each surgeon and for both cataract extraction techniques.

The monkey eyes demonstrated a 34.7% cell loss in the control eyes and a 32.6% cell loss in the methylcellulose eyes. This difference was not statistically significant.

Table 1. Endothelial cell count in cats and monkeys operated on with and without 2% methylcellulose.

Model	Mean Endothelial Cell Count (cells/mm ²)		% Cell Loss
	Preoperative	90-Days Postoperative	
Cat (n = 21)			
Control	2400	1973	17.8
2% Methylcellulose	2386	2131	10.7
P	NS*	<0.01	<0.01
Monkey (n = 5)			
Control	2660	1738	34.7
2% Methylcellulose	2723	1836	32.6
P	NS	NS	NS

*NS = not significant

DISCUSSION

Two percent methylcellulose proved to be a safe and effective surgical adjunct in cataract-implant surgery in cat and monkey models.

The three surgeons agreed that the 2% methylcellulose increased the facility of cataract removal and posterior chamber lens implantation. The only disadvantage noted was an occasional accumulation of tiny air bubbles within the methylcellulose during the performance of posterior chamber phacoemulsification. This accumulation of a few fine air bubbles when using viscoelastic substances to protect the corneal endothelium during posterior chamber phacoemulsification has been noted by one of us (RLL) with sodium hyaluronate (Healon[®]) and chondroitin sulfate in human patients.

Clinically, there was no increase in inflammation associated with the 2% methylcellulose. A more comprehensive evaluation of this subject will be addressed in a later paper in which careful histopathologic evaluation of each eye in this study will be reported.

No clinically or statistically significant elevation in IOP was noted between the methylcellulose and control eyes from 24 hours to 90 days postoperatively. MacRae et al. have reported a significant elevation in IOP in rabbits and monkeys when using sodium hyaluronate, 0.4% methylcellulose, and 20% chondroitin sulfate when it is measured between one and ten hours postoperatively.⁴ Since IOP was not measured in any animal in this study until 24 hours postoperatively, we cannot comment on the incidence of any early transient IOP elevation.

In human patients the corneal thickness as measured by pachometry is considered to be a valuable indirect measure of overall corneal endothelial function. In the cat model an increase in corneal thickness was noted in both control and methylcellulose eyes at seven days postoperatively. The corneal thickness in the control eyes increased slightly further at 90 days, whereas the 2% methylcellulose eyes demonstrated some corneal deturgescence. The increase in corneal thickness was not discernible clinically and all corneas remained clear.

In the monkey eyes, no clinically or statistically significant increase in corneal thickness was noted at 90 days postoperatively although the endothelial cell loss was approximately twice as great in the monkey eyes as in the cat eyes. These results suggest that corneal thickness is a relatively insensitive measure of mild to moderate corneal endothelial damage and place

increased importance on the measurement of corneal endothelial cell counts.

The most important factor in establishing the efficacy of a viscoelastic substance is its ability to reduce corneal endothelial cell loss during surgery. Two percent methylcellulose decreased the central corneal endothelial cell loss in the hands of each surgeon using Kelman phacoemulsification or planned extracapsular cataract extraction and posterior chamber lens implantation. In the cat model, control eyes lost an average of 17.8% of their central corneal endothelial cell density, whereas methylcellulose eyes lost 10.7%, a result that is statistically significant ($P < 0.01$). Monkey eyes demonstrated a larger central endothelial cell loss than cat eyes. Although the endothelial cell loss was reduced slightly in methylcellulose eyes, the results were not statistically significant. The cell loss in the monkey is most likely due to its small eye, 8-9 mm corneal diameter versus 14-15 mm corneal diameter in the cat. The smaller anterior chamber in the monkey increased the opportunity for contact with instruments or IOL and also increased the apparent turbulence of the irrigating solutions. We therefore feel the cat is superior to the monkey as a model for evaluating the impact of surgery on the corneal endothelium. We recommend cats or a primate with a large eye for future studies.

We conclude that 2% methylcellulose is a safe and effective viscoelastic surgical adjunct during cataract-lens implant surgery in cat and monkey models. Other authors have also demonstrated the safety of its intraocular use in human lens implantations.^{5,6} We feel that a controlled investigation of 2% methylcellulose in human cataract surgery and lens implantation is warranted.

REFERENCES

1. Kaufman HE, Katz J: Endothelial damage from intraocular lens insertion. *Invest Ophthalmol Vis Sci* 15:996-1000, 1976
2. Miller D, Stegmann R: *Healon; A Comprehensive Guide*. New York, John Wiley & Sons, Inc, 1983
3. Soll DB, Harrison SE, Arturi FC, Clinch T: Evaluation and protection of corneal endothelium. *Am Intra-Ocular Implant Soc J* 6:239-242, 1980
4. MacRae SM, Edelhauser HF, Hyndiuk RA, Burd EM, et al: The effects of sodium hyaluronate, chondroitin sulfate, and methylcellulose on the corneal endothelium and intraocular pressure. *Am J Ophthalmol* 95:332-341, 1983
5. Fechner PU, Fechner MU: Methylcellulose and lens implantation. *Br J Ophthalmol* 67:259-263, 1983
6. Aron-Rosa D, Cohn HC, Arog J-J, Douquety C: Methylcellulose instead of Healon[®] in extracapsular surgery with intraocular lens implantation. *Ophthalmology* 90:1235-1238, 1983

Report and management of the sunrise syndrome

S. Gregory Smith, M.D.
Richard L. Lindstrom, M.D.
Minneapolis, Minnesota

ABSTRACT

We report a case in which a posterior chamber lens subluxated superiorly, resulting in progressive loss of vision.

Key Words: inferior zonular disinsertion, McCannel suture, posterior chamber lens, sunrise syndrome

The subluxation of a posterior chamber intraocular lens (IOL) inferiorly (sunset syndrome) has been described.^{1,2} The following report describes a patient in whom a posterior chamber lens subluxated superiorly, resulting in progressive loss of vision.

CASE REPORT

A 72-year-old white female had an extracapsular cataract extraction in the left eye on October 27, 1982. Intraoperatively, the surgeon noted rupture of the zonules inferiorly for at least 90° prior to posterior chamber lens implantation.

A vaulted, flexible loop, posterior chamber IOL (Kratz 72-10) was inserted into the sulcus and rotated to the horizontal position. The optic, however, was encircled by the inferior capsular flap. Postoperatively, the visual acuity improved initially to 20/25. The lens later migrated progressively superiorly as the posterior capsule began to contract. The vitreous face remained intact.

On January 25, 1983, the patient was referred to the University of Minnesota for consultation. The inferior edge of the optic was in the middle of the pupillary space (Figure 1) in the visual axis. The visual acuity was best corrected to 20/80 with pseudophakic correction and 20/60 with aphakic correction. Dilation did not improve the aphakic acuity.

The patient was not satisfied with her vision and on April 22, 1983, she underwent surgical repositioning of the lens in the following manner: Under sodium hyaluronate (Healon®), the optic was disengaged from the capsular bag by gentle traction with a Sinsky hook.

Reprint requests to S. Gregory Smith, M.D., 2323 Pennsylvania Avenue, Wilmington, Delaware 19806.

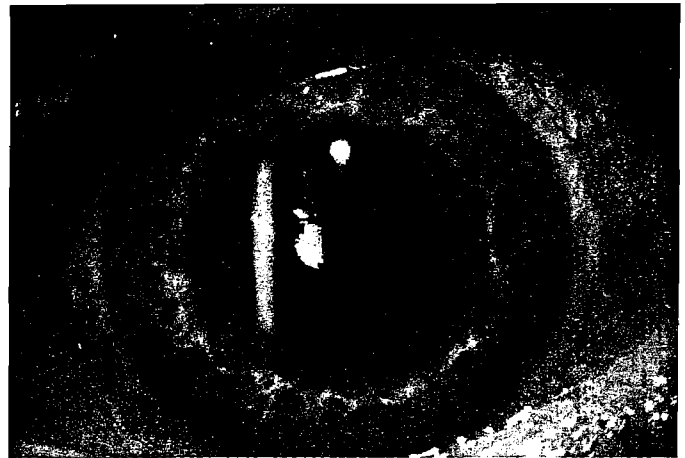

Fig. 1. (Smith) Lens optic displaced superiorly.

Only mild resistance was encountered. The lens was then rotated by the positioning holes until it centered well. We then elected to suture the IOL loops to the iris using a modified McCannel suture technique. The optic was prolapsed into the anterior chamber, creating a total pupil capture. The posteriorly angulated loops were visible as linear ridges indenting the iris (Figure 2). Two iris-loop sutures were placed by passing a

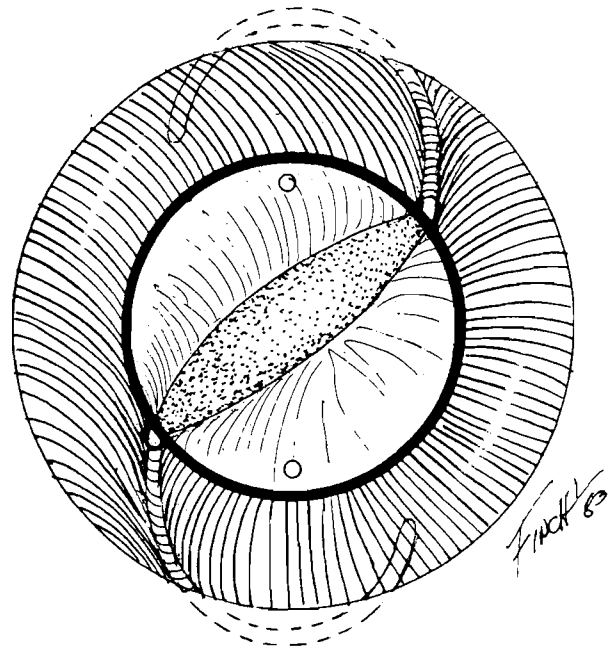


Fig. 2. (Smith) Lens optic prolapsed into the anterior chamber, inducing total pupillary capture.

sterile disposable 25-gauge needle through a limbal stab incision across the anterior chamber, under the iris behind the loop and back out a second limbal stab incision (Figure 3). A 10-0 polypropylene (Prolene®) suture was then threaded through the needle aperture until it crossed the anterior chamber inside the needle.

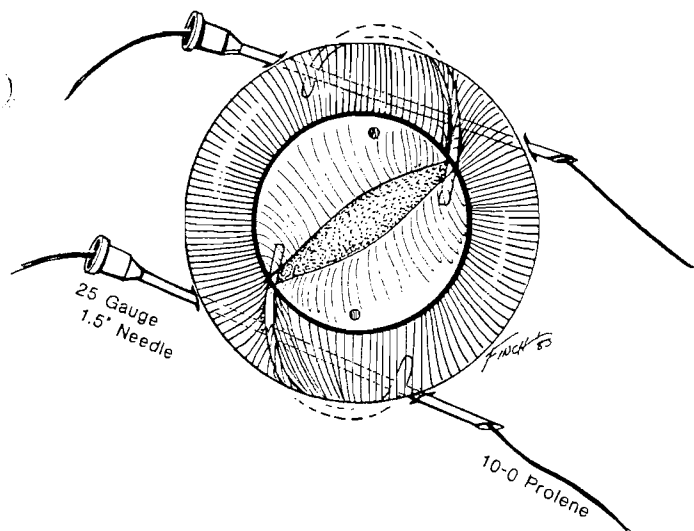


Fig. 3. (Smith) Suture passed through the iris, behind the haptic, and back through the iris after being threaded through a 25-gauge needle that was introduced through the limbus.

The needle was then removed. A micro-iris-hook was introduced through the stab incision closest to the haptic and the suture was withdrawn from the anterior chamber. It was tightened, tied, trimmed, and allowed to retract into the eye. The optic was then repositioned into the posterior chamber. Two sphincterotomies were performed around the pupil (Figure 4). A central discission completed the procedure.

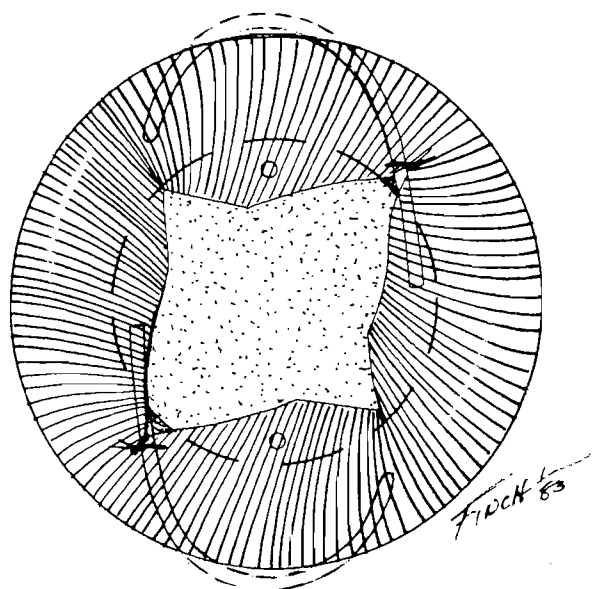


Fig. 4. (Smith) Trimmed sutures tied; IOL optic repositioned in the posterior chamber; sphincterotomies performed.

The patient was seen in follow-up three months later on July 21, 1983, at which time the visual acuity was 20/20-1 (Figure 5). The eye was white and quiet; there

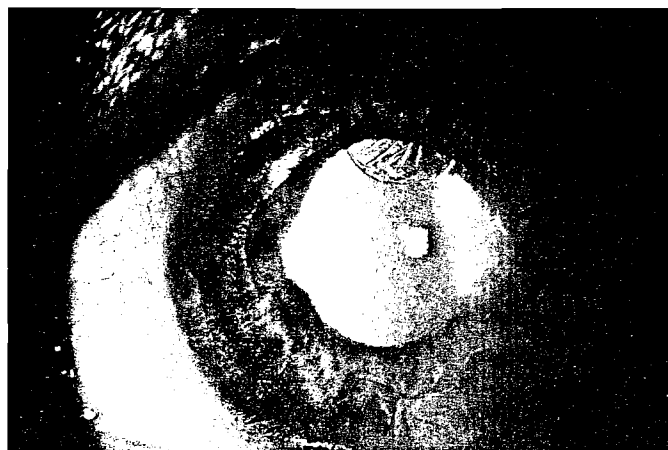

Fig. 5. (Smith) Appearance of repositioned IOL three months postoperatively.

were a few cells in the anterior chamber on slitlamp examination. The intraocular pressure was 13 mm Hg. Specular microscopy revealed a drop in endothelial cell count from 1,980 cells/mm² preoperatively to 1,670 cells/mm² postoperatively.

DISCUSSION

This patient presented with a superior migration of a posterior chamber IOL that resulted in progressive loss of visual acuity. We have termed this the sunrise syndrome because, like the sunset syndrome, it is a potential complication of posterior chamber lenses in the face of inferior zonular disinsertion. In this patient with an inferior zonular disinsertion, the optic was within the capsular bag and fibrosis of the posterior capsule with resultant contracture pulled the optic superiorly out of position. This mechanism is different from that in the sunset syndrome where the zonular disinsertion removes support for the posterior chamber loops and the lens slips inferiorly into the vitreous cavity.

Surgical intervention in the sunrise (or sunset) syndrome is indicated when the patient becomes disabled by the reduction in visual acuity or there is impending loss of the IOL into the vitreous.

The sunset syndrome has been managed by removing the IOL, placing a McCannel suture, or simply inducing pupillary capture.^{1,2} We elected to manage this case of sunrise syndrome by lysing capsular attachments to the IOL, recentering the lens, and placing two modified McCannel sutures.

In patients where inferior zonular disinsertion is noted prior to lens implantation, we currently recommend either (1) horizontal placement of the IOL into the sulcus with care to keep the optic outside the capsular bag combined with consideration of a McCannel suture; or (2) primary implantation of an anterior chamber lens.

SUMMARY

A patient underwent extracapsular cataract extraction and implantation in the presence of intraoperatively recognized zonular disinsertion and ultimately developed decentration of the lens superiorly. This was treated by freeing the lens from the capsular bag and suturing it in place with modified McCannel sutures. Postoperatively, the patient achieved good visual acuity. Recommendations for lens implantation in the presence of inferior zonular disinsertion include horizontal placement of the IOL in the sulcus with the optic outside the capsular bag combined with consideration of a McCannel suture; or insertion of an anterior chamber lens.

REFERENCES

1. Clayman HM, Jaffe NS, Galin MA: *Intraocular Lens Implantation: Techniques and Complications*. St. Louis, CV Mosby Co, 1983, p 245
2. Emery JM, Jacobson AC: *Current Concepts in Cataract Surgery; Selected Proceedings of the Seventh Biennial Cataract Surgical Congress*. New York, Appleton-Century-Crofts, 1982, p 141