

Papilla Formation Between Adjacent Implants Using Computer Guided Surgery

Paul A. Schnitman DDS

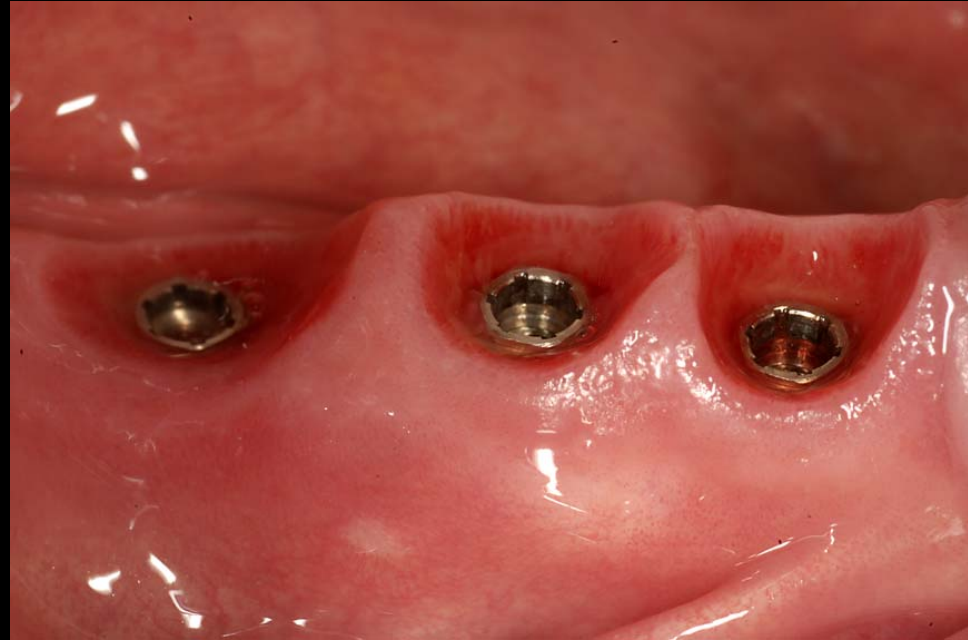
Wellesley Hills, MA, USA

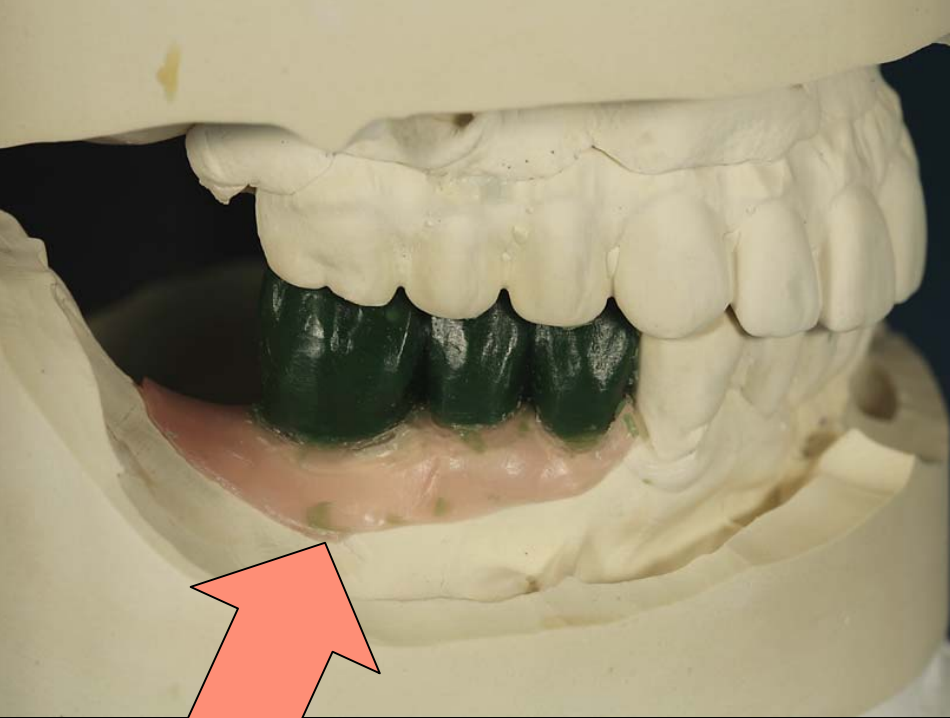


Papilla Formation

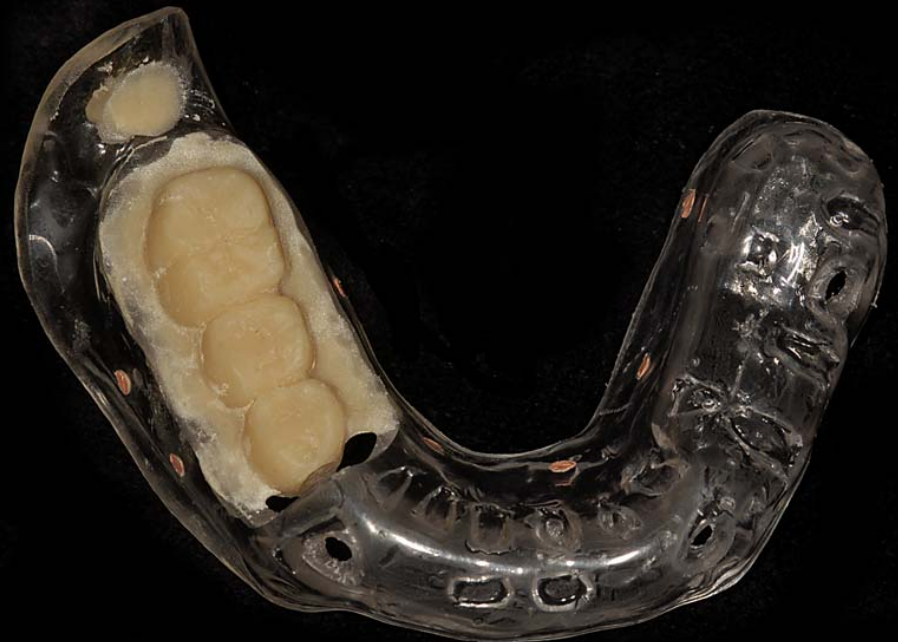4 patients/9 implants

- Computer guided
- Flapless placement
- Immediate provisional restoration
- Provisional restoration not removed

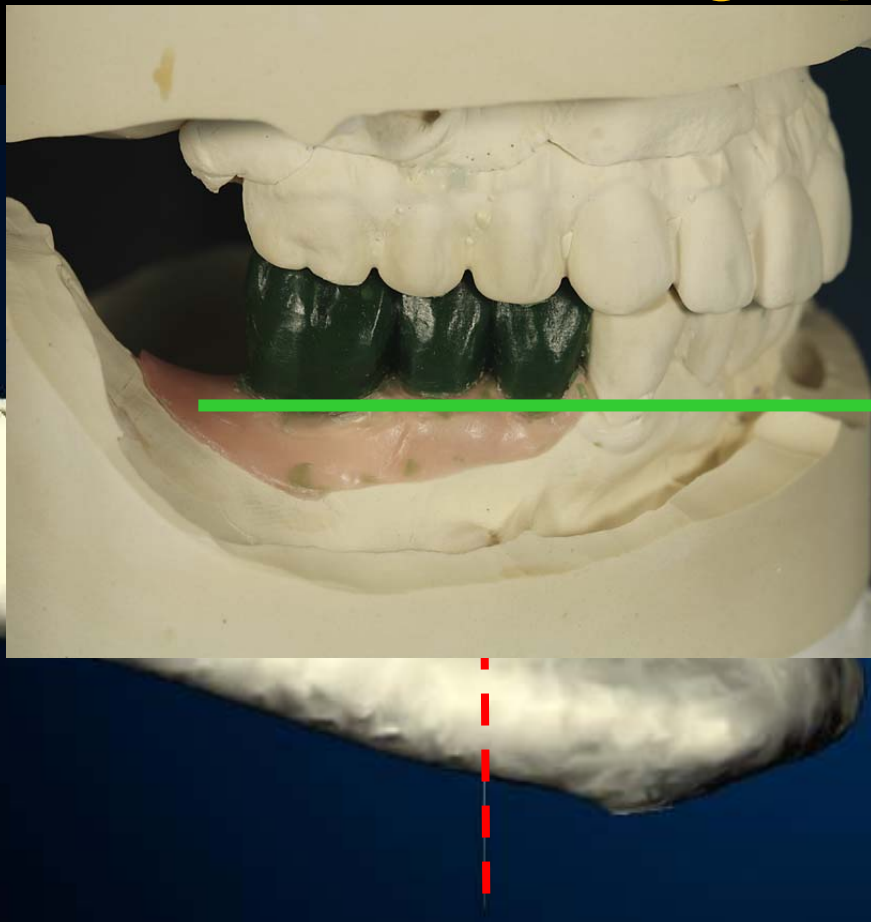




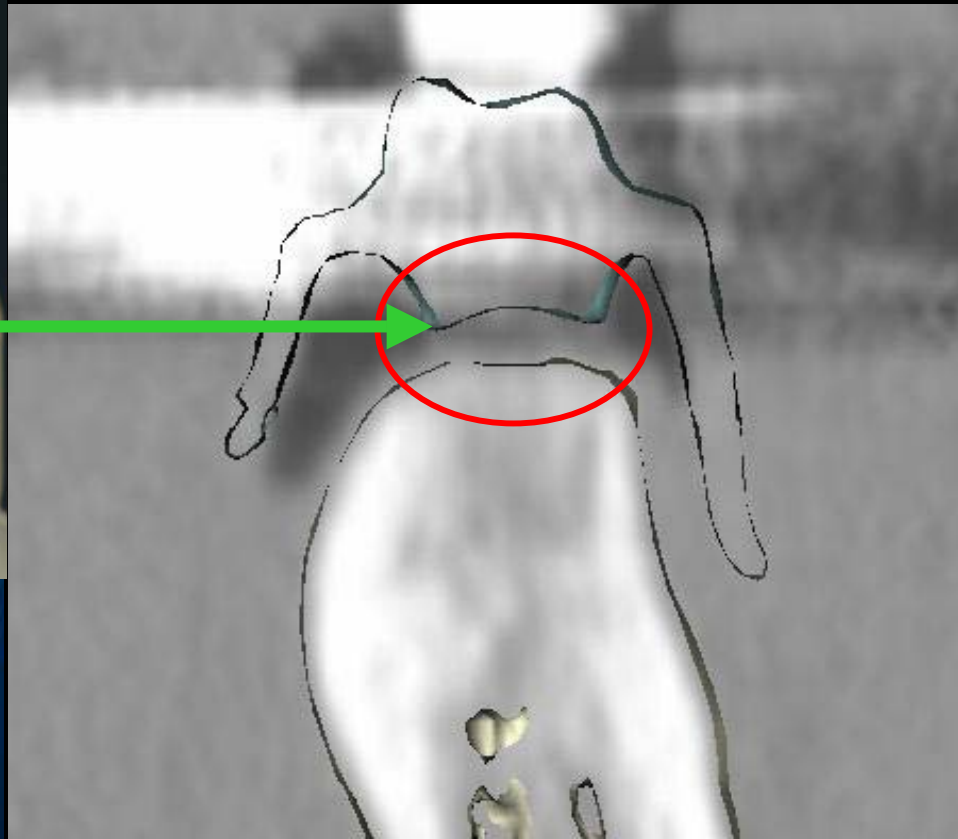
Radiographic Guide



Radiographic Guide

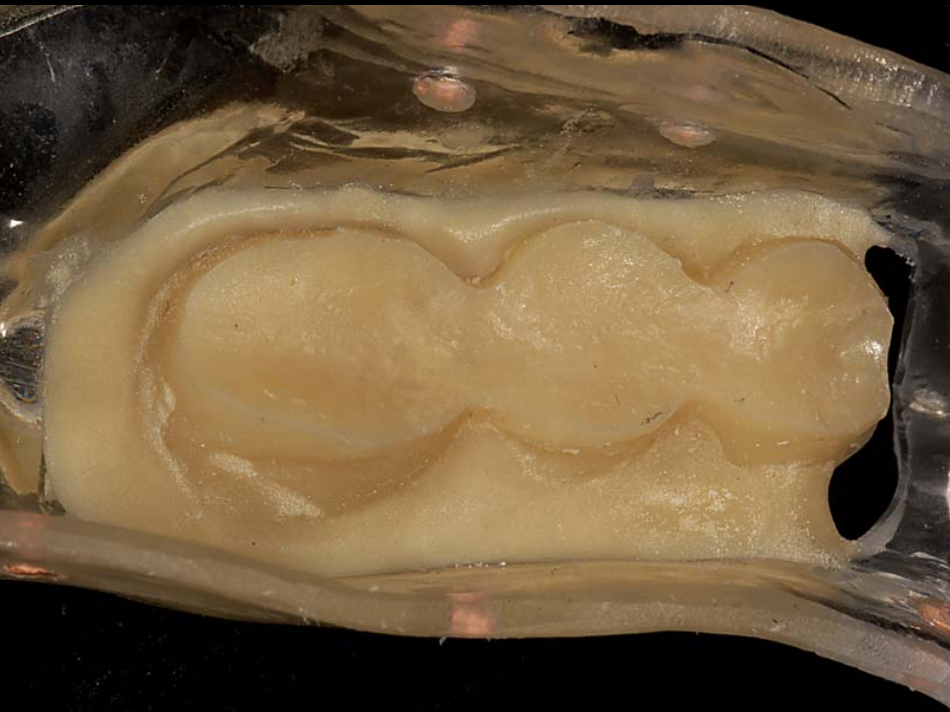

virtual 3-D

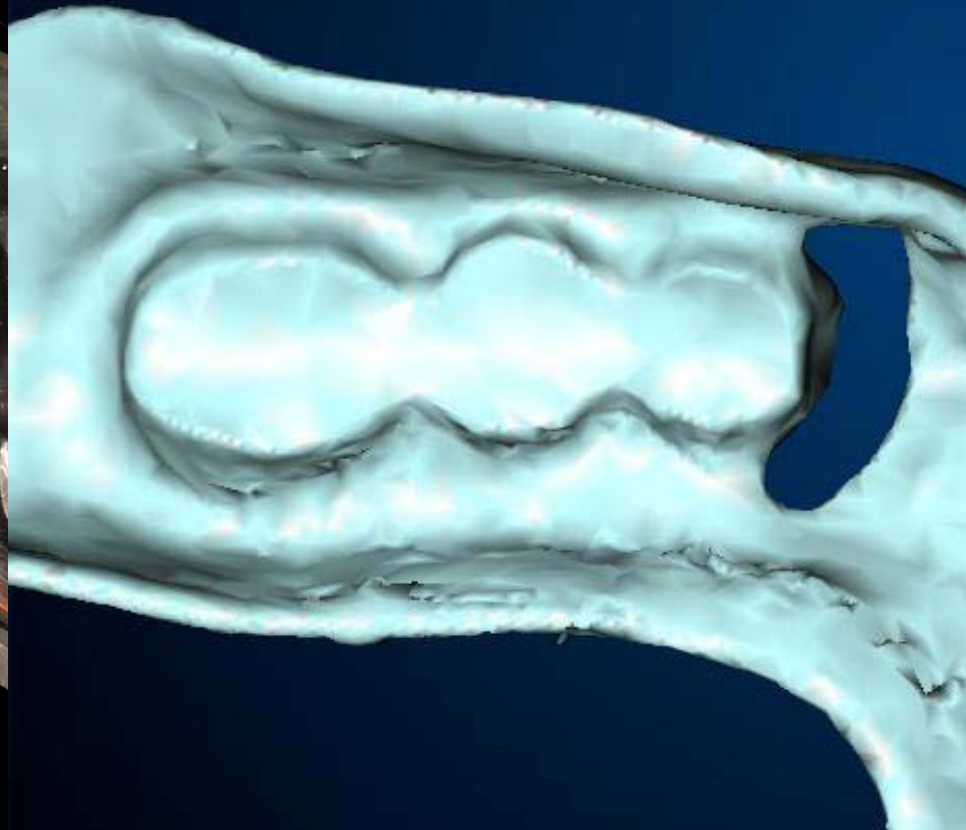


virtual X-S

Radiographic Guide

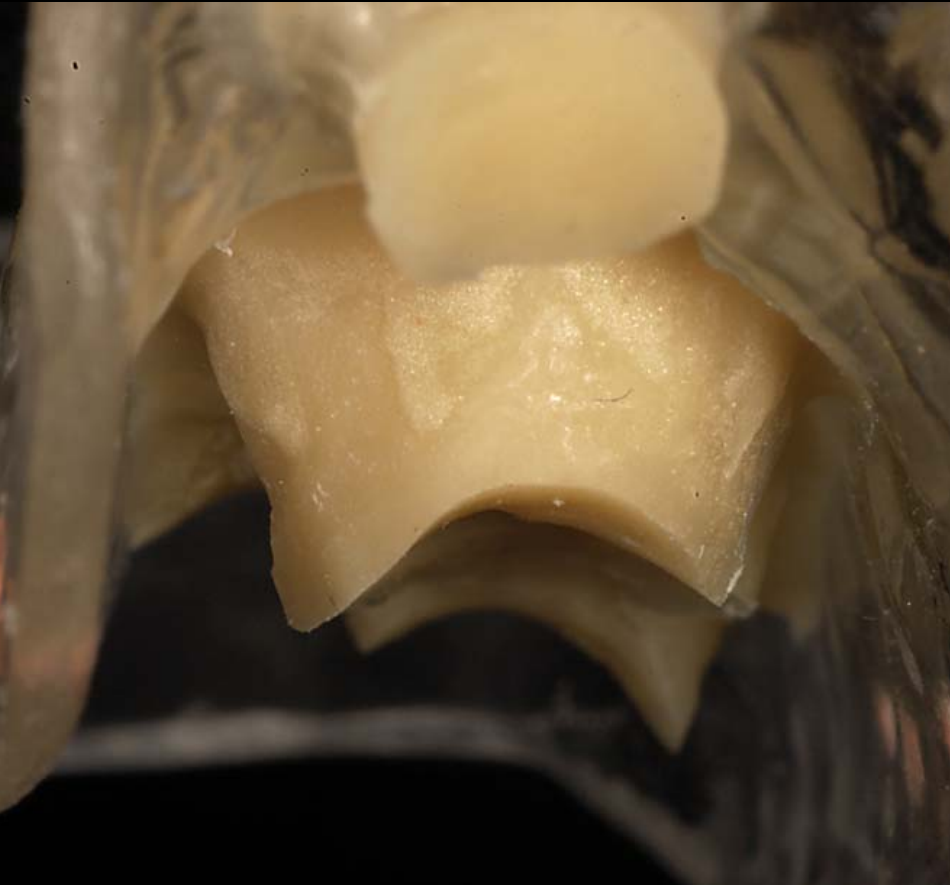


actual

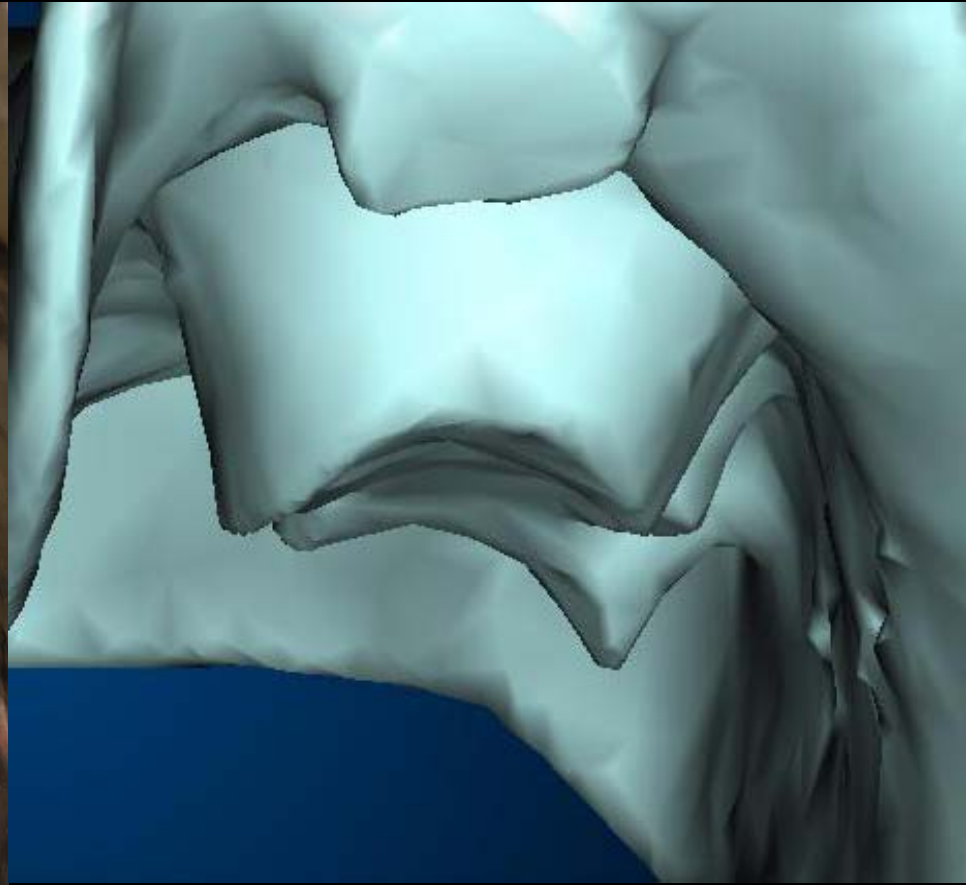


virtual

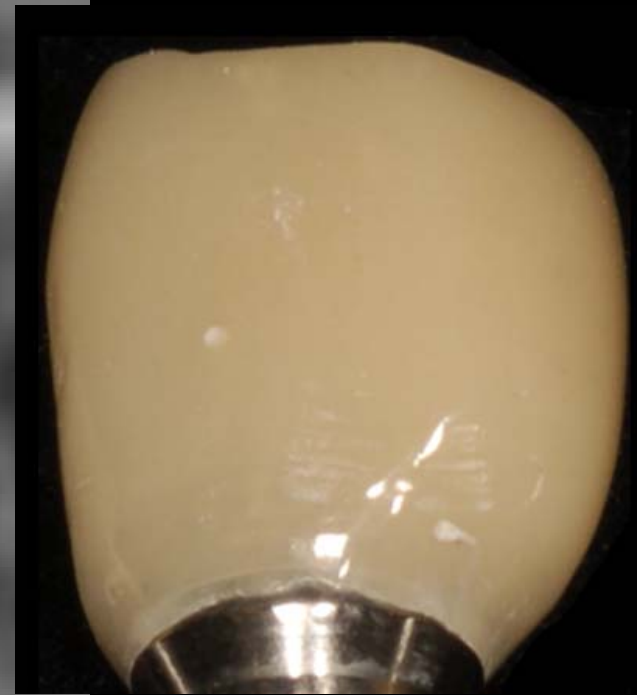
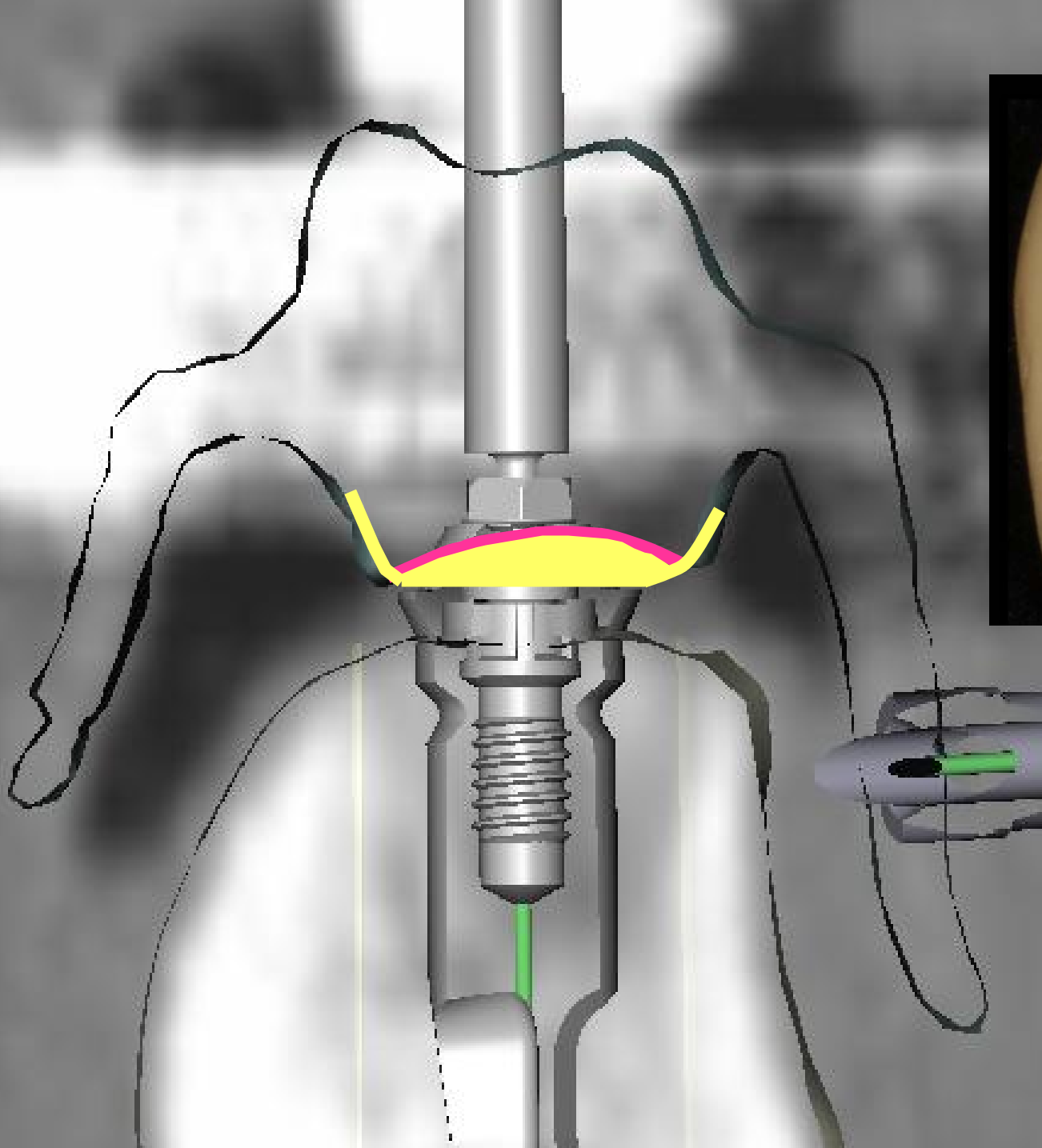
Radiographic Guide

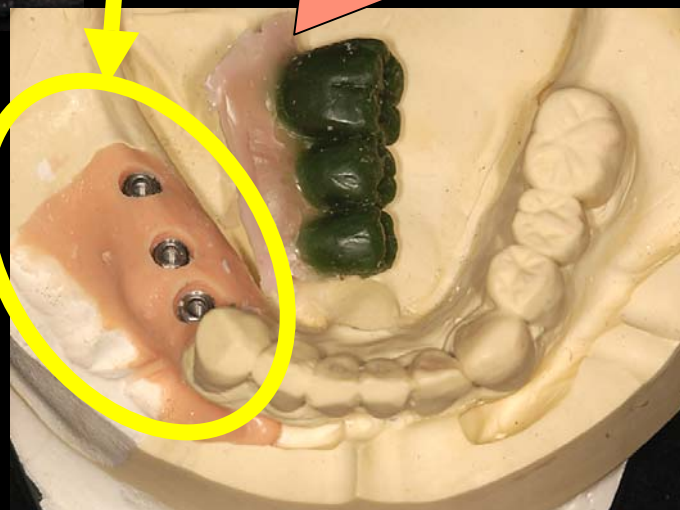
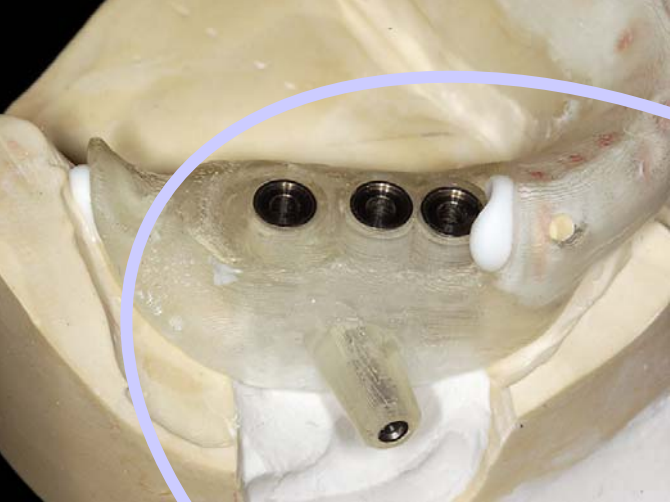


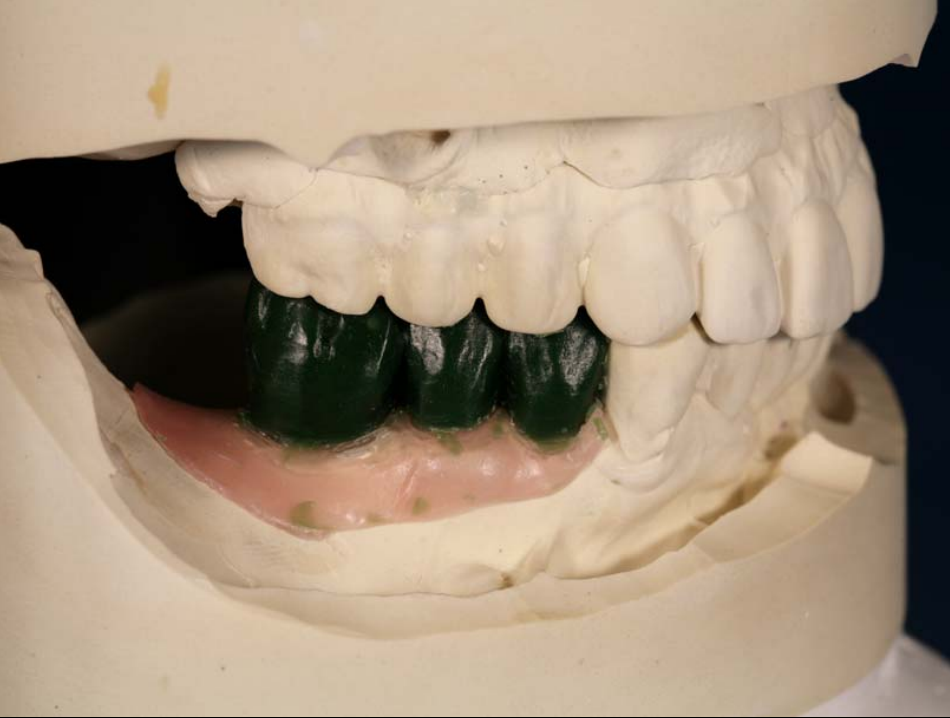actual



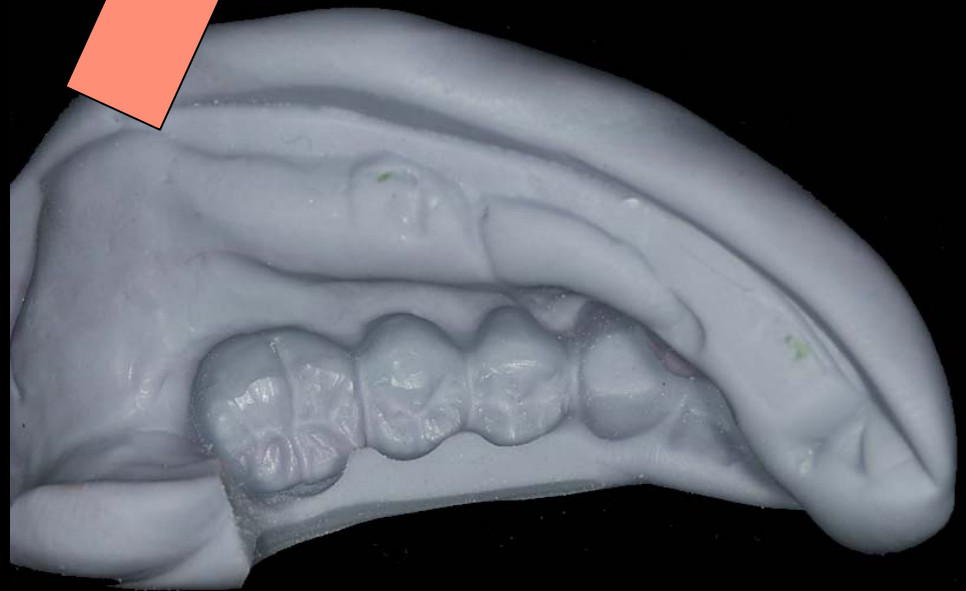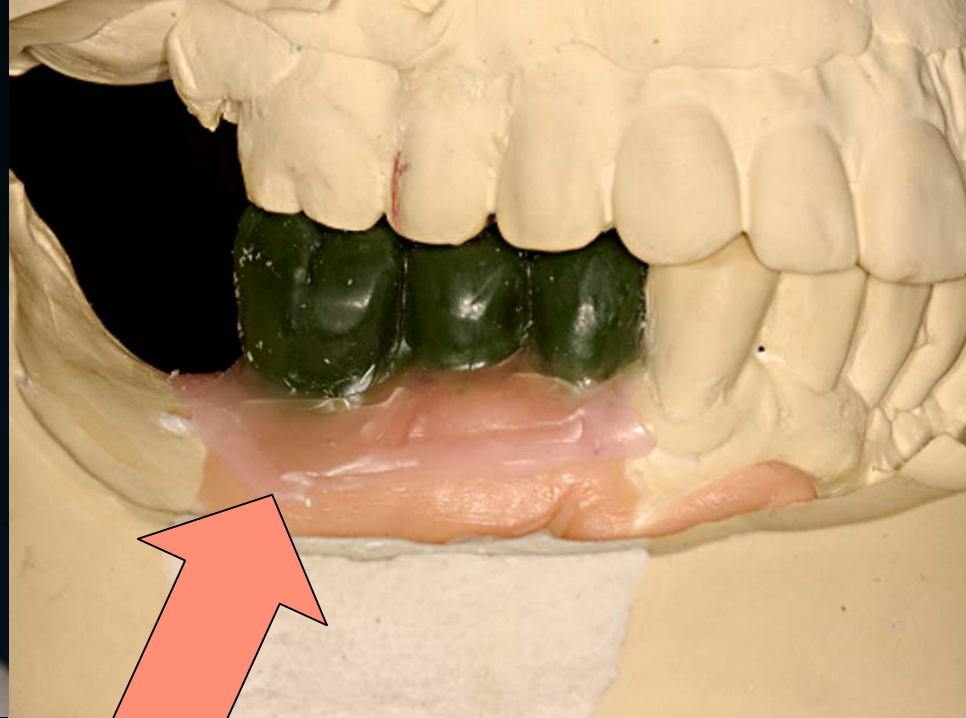
virtual

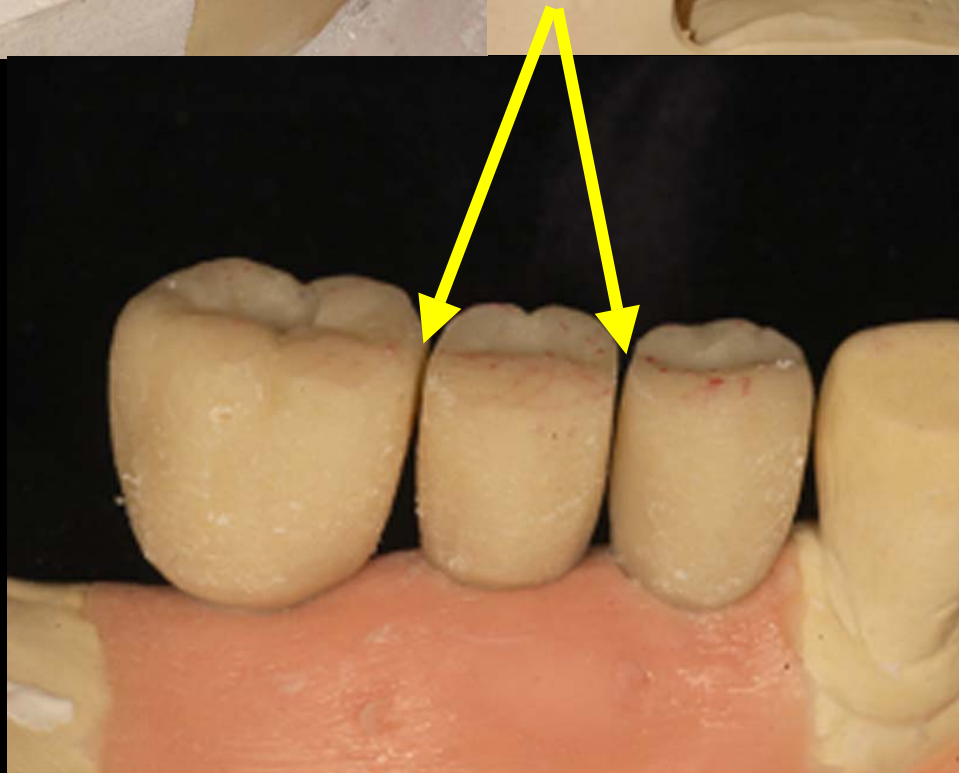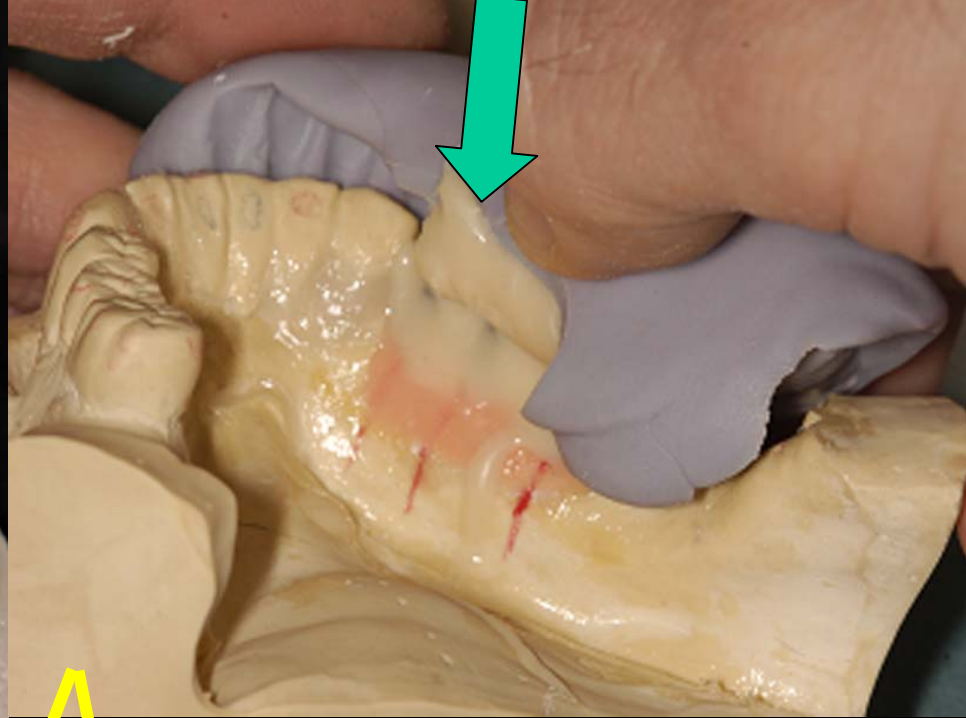
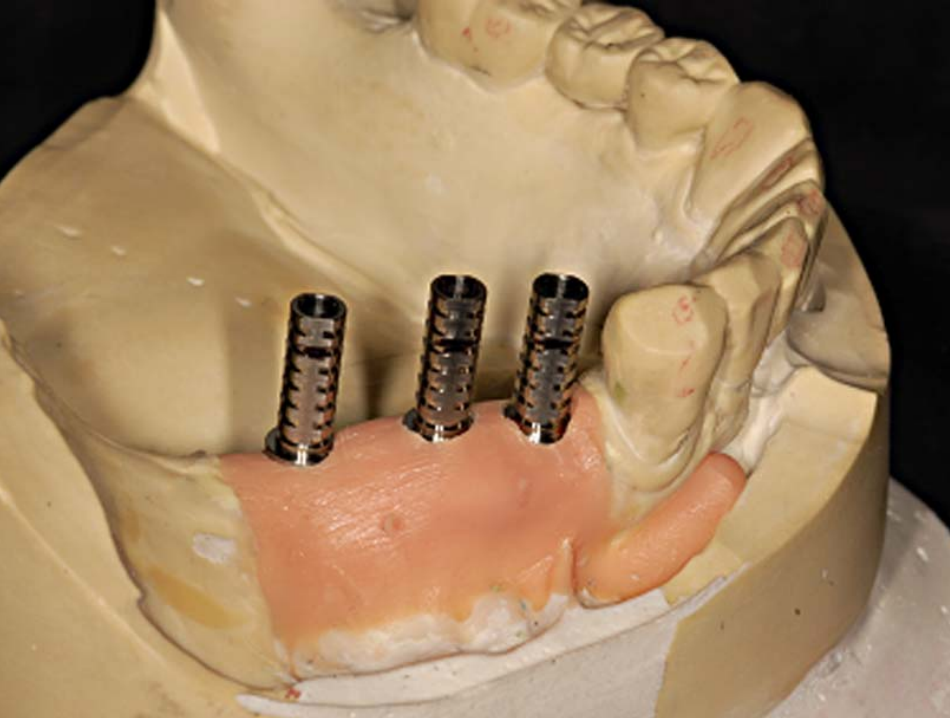


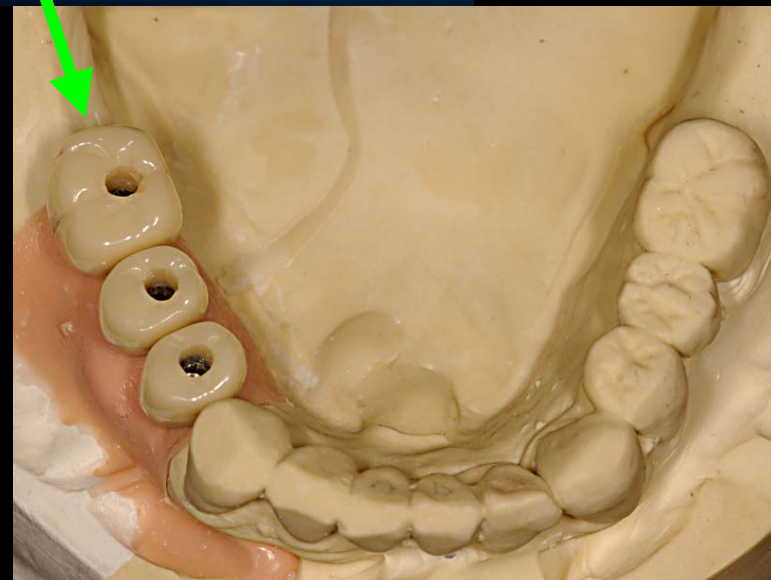
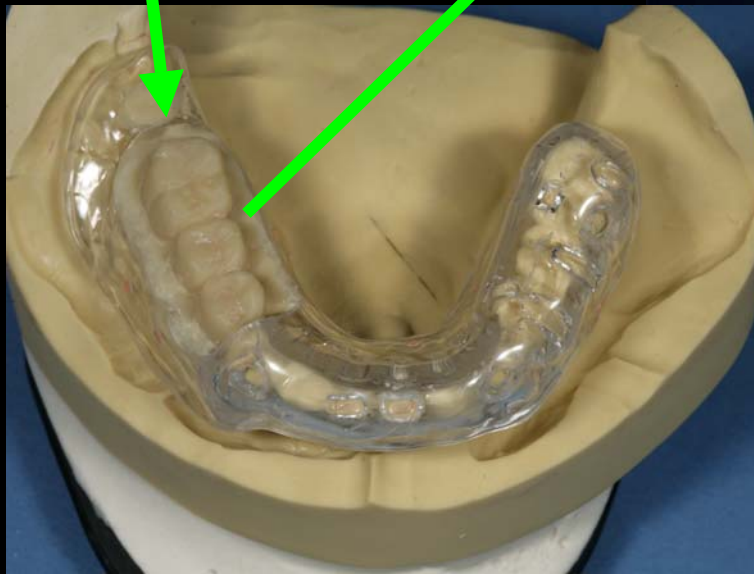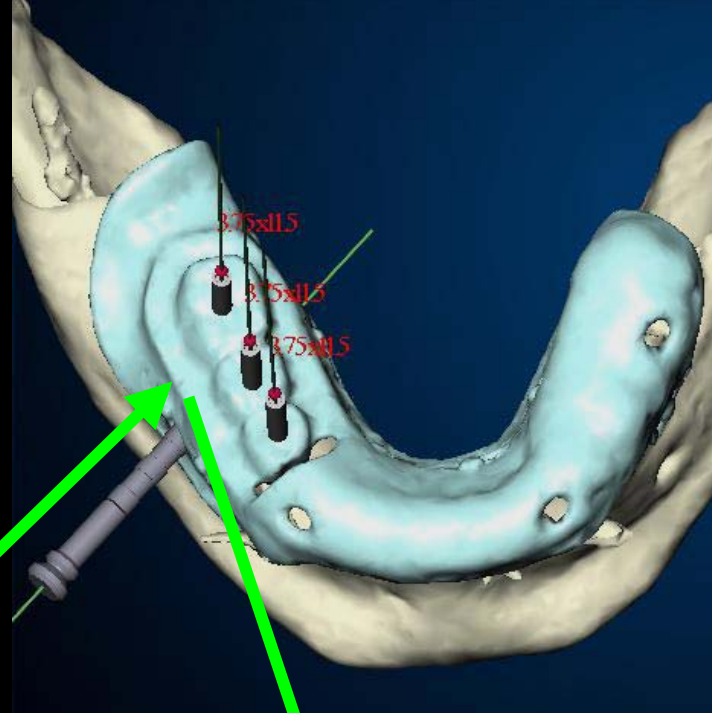
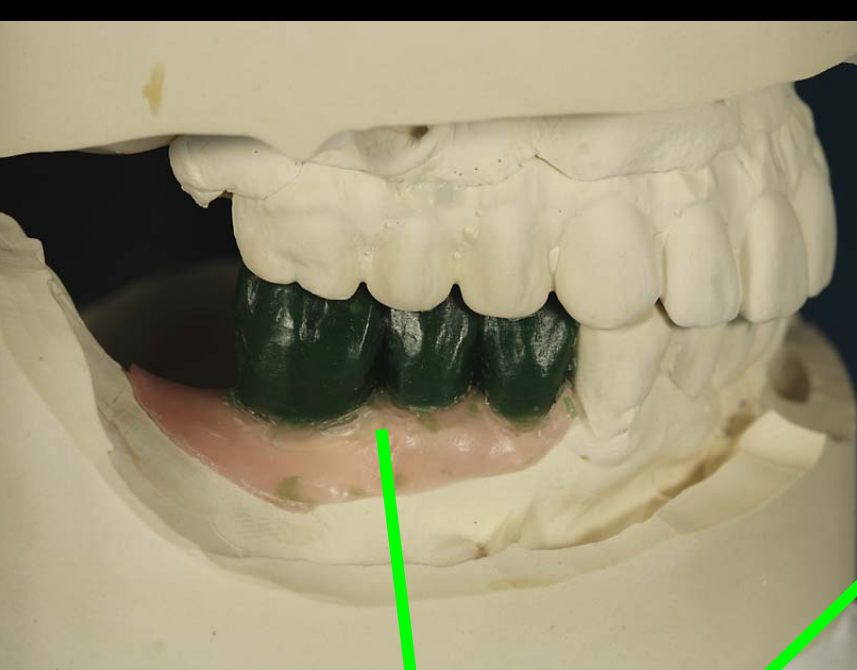




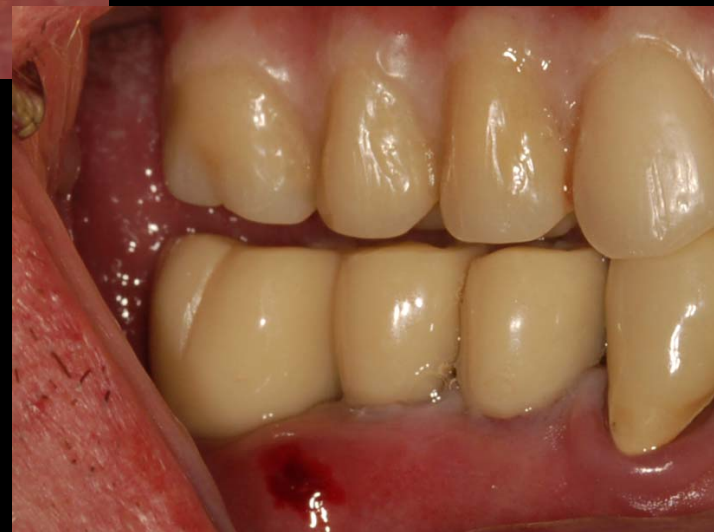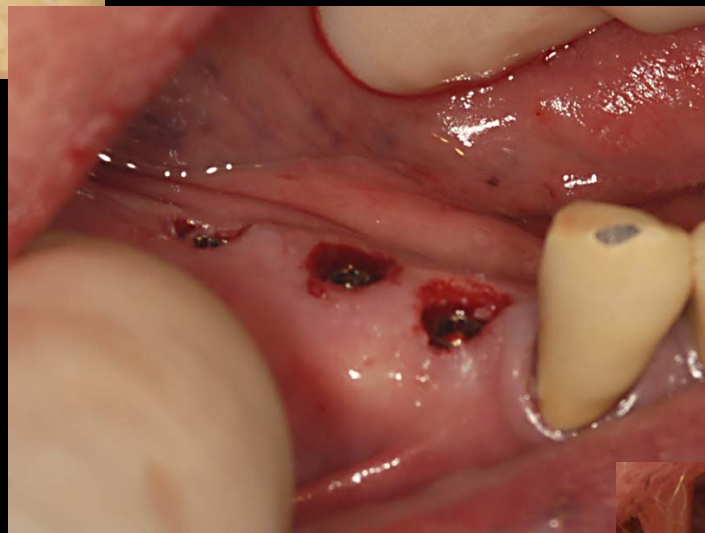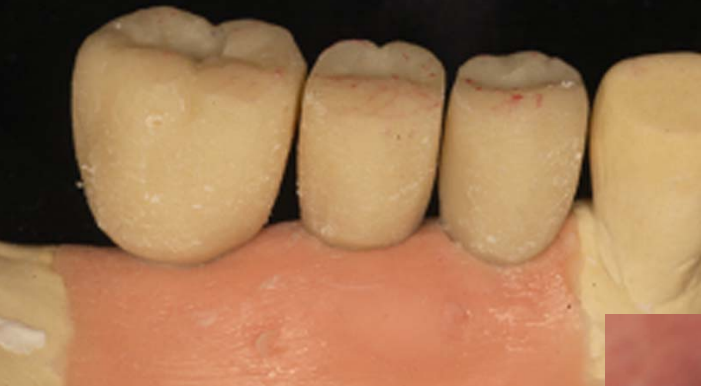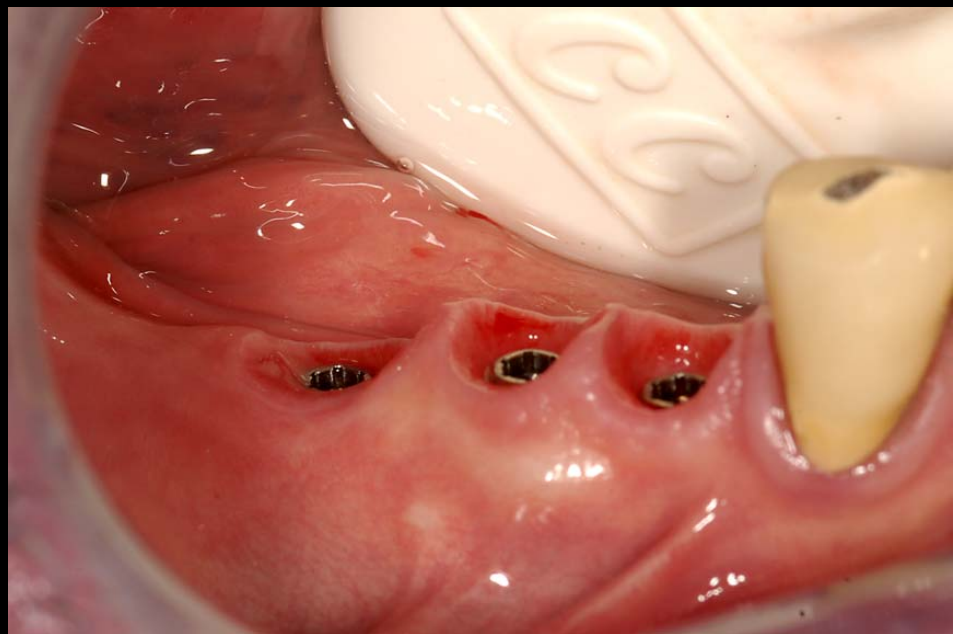
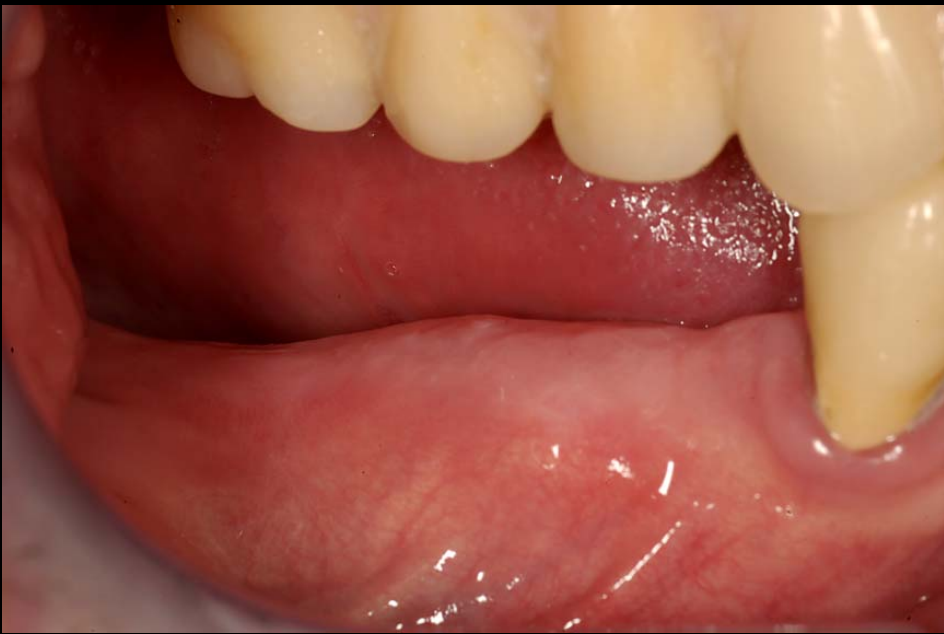before retrofitting

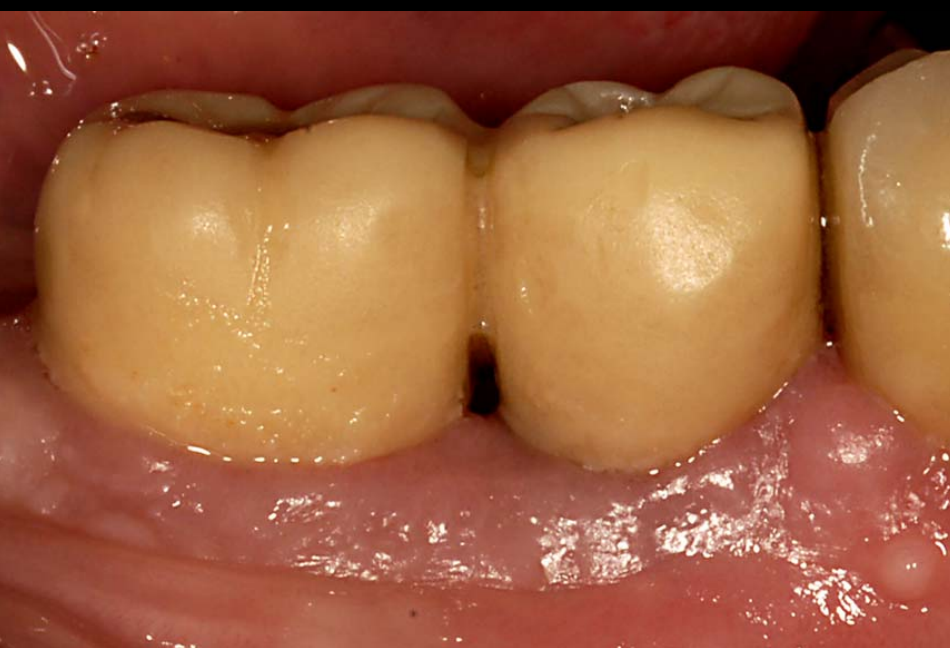




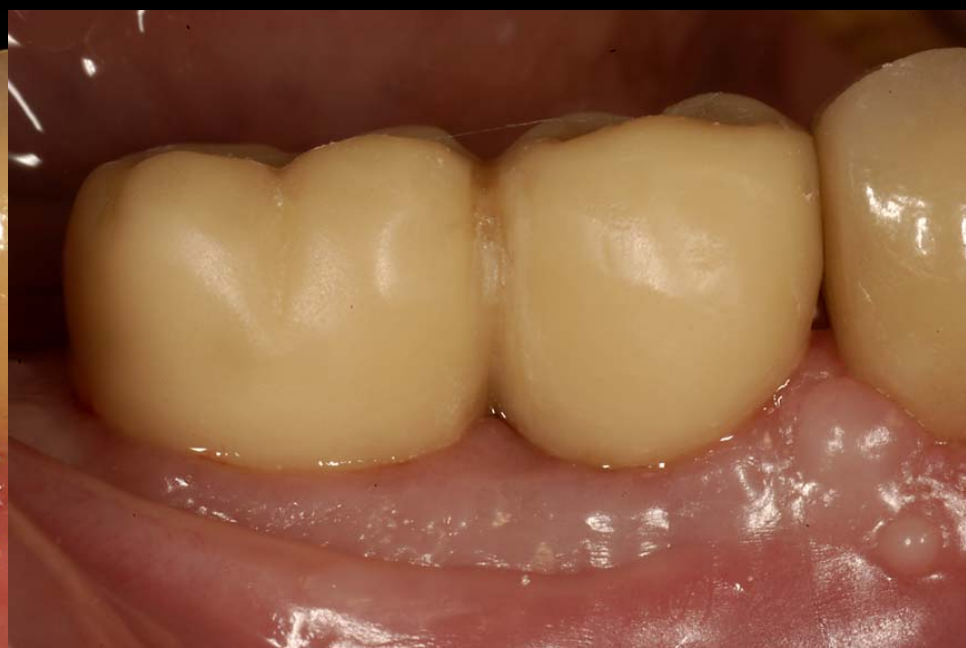




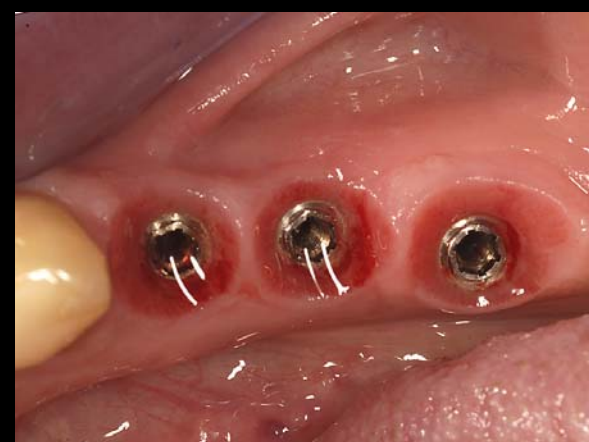
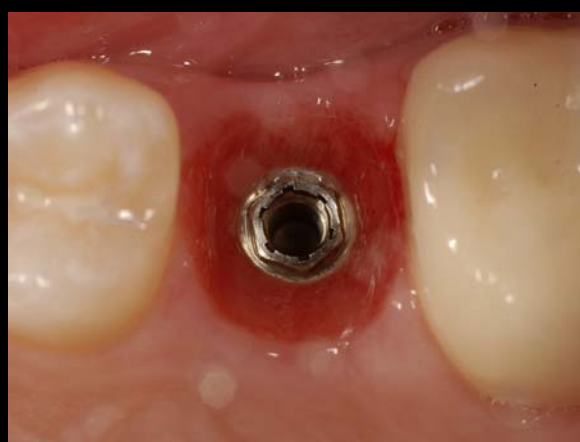
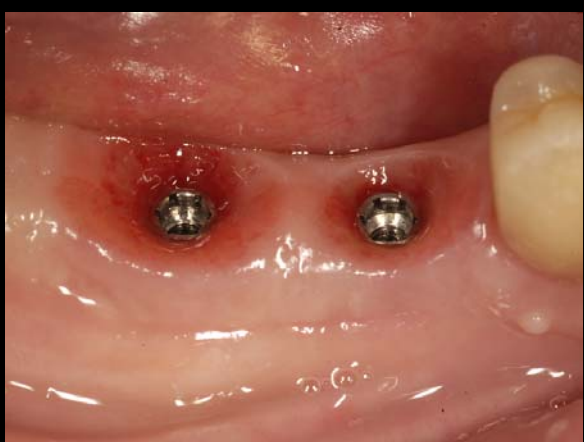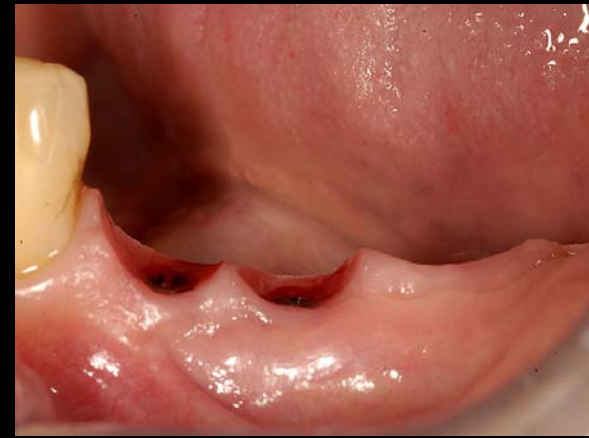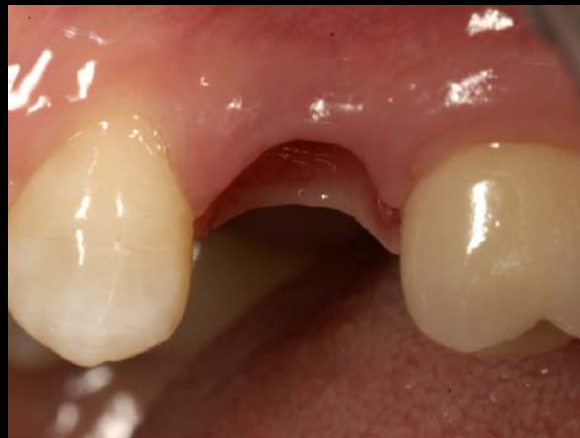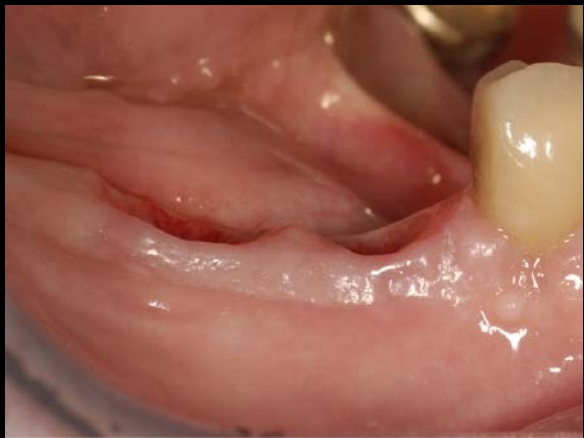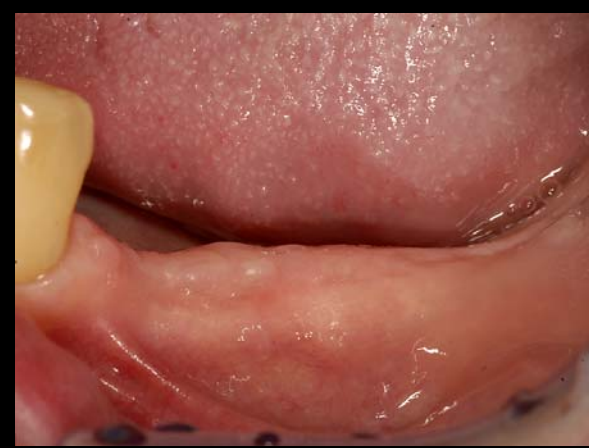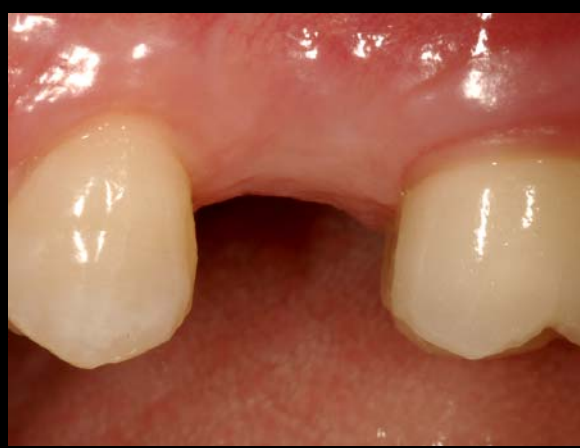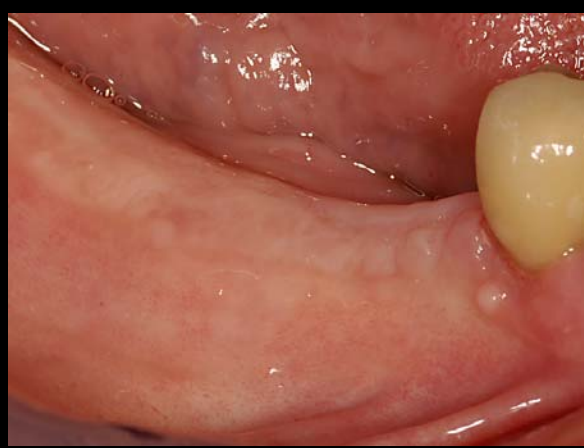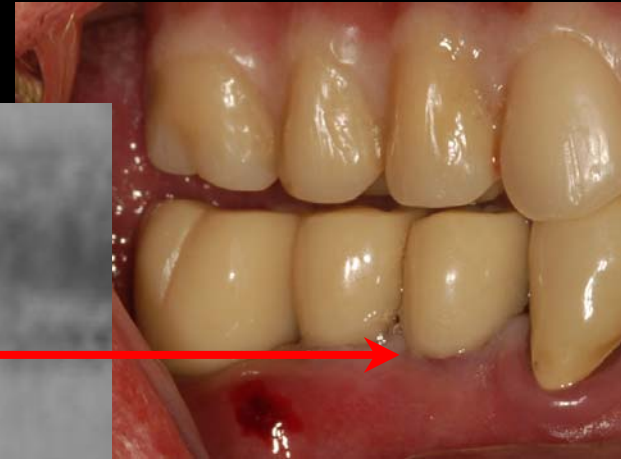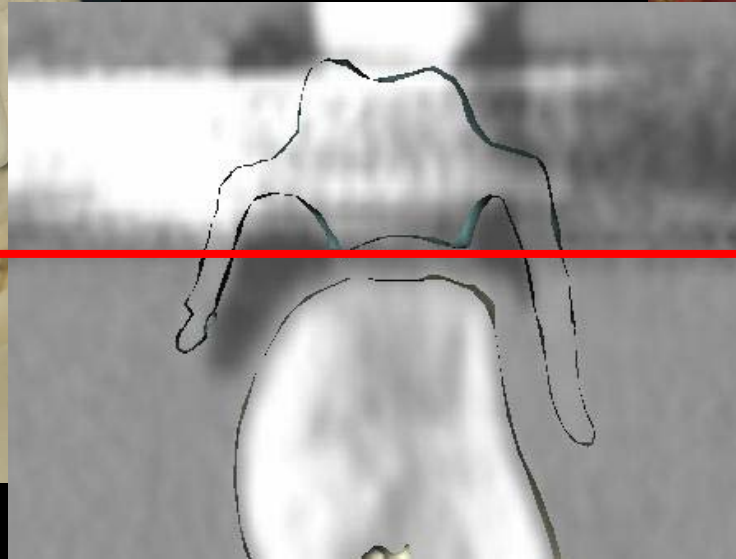
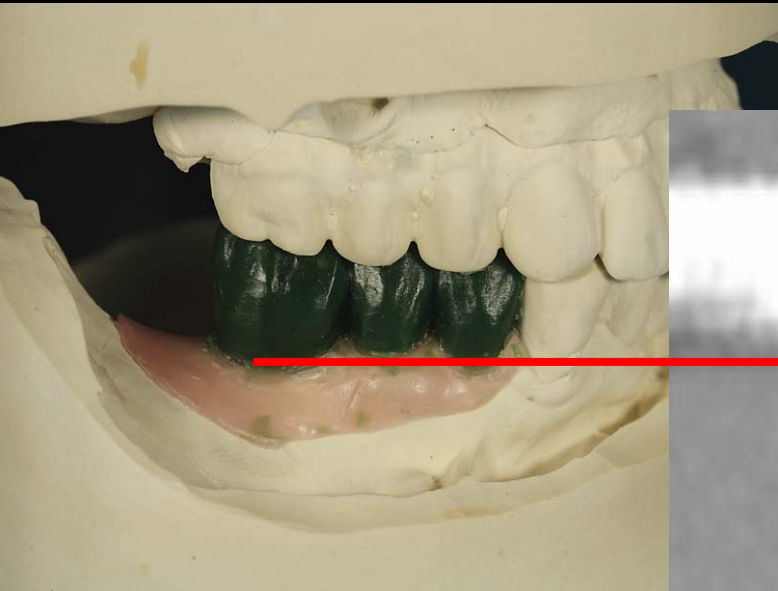
1 month post-op



3 months post-op



Conclusion



“tale of a wax-up”

Radiographic Results

