
Ten-Year Results for Brånemark Implants Immediately Loaded With Fixed Protheses at Implant Placement

Paul A. Schnitman, DDS, MSD*/Peter S. Wöhrle, DMD, M Med Sc**/
Jeffrey E. Rubenstein, DMD, MS***/John D. DaSilva, DMD, MPH, ScM****/
Nai-Huei Wang, DDS, MS*****

This investigation was initiated to develop a method to provide patients with a fixed provisional prosthesis placed at the time of implant placement. Sixty-three standard 3.75-mm Nobel Biocare implants of varying lengths were placed into mandibular sites in 10 patients and followed for up to 10 years. Twenty-eight implants were immediately loaded at implant placement, providing support for fixed provisional protheses, while 35 adjacent implants were allowed to heal submerged and stress-free. Following a 3-month healing period, the submerged implants were exposed and definitive reconstruction was accomplished. All 10 protheses supported by 28 implants placed into immediate function at the time of implant placement were successful during the 3-month healing period. Of these 28 implants placed into immediate function, 4 ultimately failed. Of the 35 submerged implants, all are osseointegrated and in function to date. Life-table analysis demonstrates an overall 10-year survival rate of 93.4% for all implants. The 10-year life-table analysis of survival is 84.7% for immediately loaded implants and 100% for submerged implants. Statistical analysis of the submerged versus immediately loaded implants demonstrates failure rates for immediately loaded implants to be significantly higher ($P = .022$ by the log rank test). These data demonstrate that although mandibular implants can be successfully placed into immediate function in the short term to support fixed provisional protheses, long-term prognosis is guarded for those implants placed into immediate function distal to the incisor region.

(INT J ORAL MAXILLOFAC IMPLANTS 1997;12:495-503)

Key words: Brånemark implants, immediately loaded implants, provisional fixed prosthesis, 10-year life-table analysis

The transitional removable prosthesis is a frequent barrier to patient acceptance of implant treatment. Whether it is a partial or a complete denture,

patients often resist the idea of wearing a removable prosthesis. The concept of such a prosthesis may be psychologically traumatic to many patients.

Patients undergoing osseointegration therapy generally either wear a removable prosthesis or else wear no prosthesis when abutment support is lacking during an extended healing period. While most edentulous patients are more tolerant of additional months of denture therapy, management of these patients can be difficult. Postoperative changes during the healing period can lead to discomfort and often necessitate frequent prosthesis adjustments.

The present study was initiated in 1986 to address these problems. A method was developed to provide patients with fixed provisional protheses placed at the time of implant placement. Treatments were planned so as to avoid compromising the long-range predictability of implant therapy for these patients, while eliminating the need for removable protheses.

*Private Practice, Implant Dentistry, Wellesley Hills, Massachusetts; Former Chairman, Department of Implant Dentistry, Harvard School of Dental Medicine, Boston, Massachusetts.

**Private Practice, Implant Dentistry, Newport Beach, California.

***Associate Professor of Prosthodontics, University of Washington, School of Dentistry, Seattle, Washington.

****Instructor in Oral Health Policy and Epidemiology; Assistant Program Director, Postdoctoral Prosthodontics, Harvard School of Dental Medicine, Boston, Massachusetts.

*****Private Practice, Santa Monica, California.

Reprint requests: Dr Paul A. Schnitman, Wellesley Hills Medical Center, 422 Worcester Street, Suite 202, Wellesley Hills, MA 02181. Fax: (617) 235-6883.

Prior to the introduction of Brånemark's protocol, the concept of placing implants into immediate function was widespread, but early results were unpredictable.¹ The introduction of Brånemark's research^{2,3} in the early 1980s opened a new era in implant treatment predictability. While Brånemark's protocol was complex, requiring two surgical procedures separated by a 4- to 6-month healing period, it significantly improved the outcome of implant treatment. In the mid 1980s, Babbush et al⁴ reported a modified approach using one-stage titanium plasma-sprayed (TPS) screws in the anterior mandible to immediately support overdentures. Subsequently, Buser et al⁵ introduced the concept of placing implants using one surgical procedure. However, the technique still required a 3- to 6-month healing period before implants could be placed into function.⁵ In 1990, 3.5-year results of treatments that placed Brånemark implants into immediate function at the time of implant placement were reported.⁶ This report presents 10-year results of this research.

Materials and Methods

In this study, 63 standard 3.75-mm Brånemark implants (Nobel Biocare, Westmont, IL) of varying

lengths were placed into the mandibular sites of 10 patients and followed for up to 10 years. All of the patients, including 6 males and 4 females, were in good health and ranged in age from 48 to 78 years. Nine of the patients were losing their remaining mandibular dentition to periodontal disease, and one was wearing a mandibular complete denture without success.

Figure 1 shows implant length (in millimeters), the location of submerged and immediately loaded implants, and the location of natural abutments for each of the 10 patients. Twenty-eight implants were immediately loaded at placement and provided support for fixed provisional prostheses. Thirty-five adjacent implants also were placed using the standard two-stage protocol, which allowed them to heal submerged and stress-free. In three patients (1, 7, and 8), natural teeth, in conjunction with immediately loaded implants, provided abutment support for fixed provisional partial dentures. In all but two patients (6 and 7), abutments were oriented in a tripod configuration (Fig 1). In patient 6, all implants were immediately loaded. In patient 7, one immediately loaded implant, placed into the second molar region, provided posterior abutment support along with natural tooth abutments for the fixed provisional partial denture. The

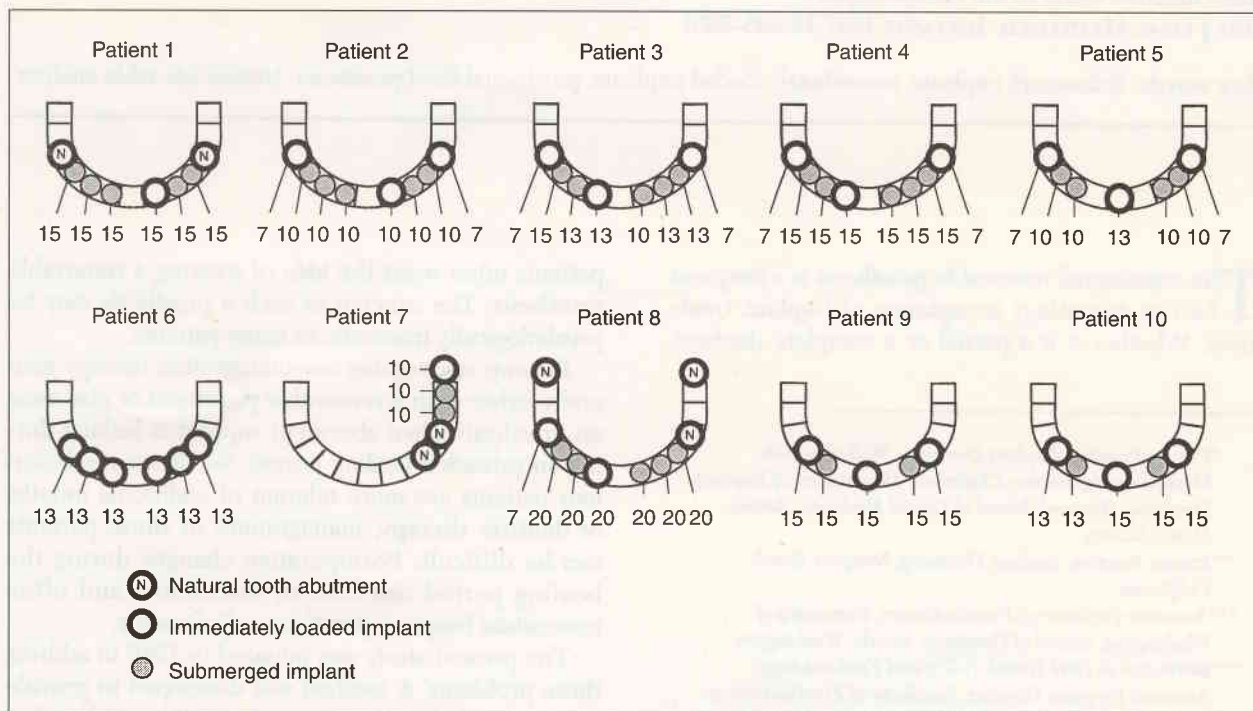


Fig 1 Location of implants and natural abutments for each of the 10 patients during their immediately loaded and healing phase. Numbers designate implant lengths in millimeters. Opposing dentitions for patients 1, 2, and 3 are complete dentures; for patients 4, 7, 8, and 10, fixed detachable implant prostheses; for patients 5 and 6, restored fixed natural dentition; and for patient 9, a four-implant, bar-retained overdenture.

opposing dentition is a complete denture in patients 1, 2, and 3; a restored full-coverage natural dentition in patients 5 and 6; a four-implant bar-retained overdenture in patient 9; and a fixed detachable implant prosthesis in patients 4, 7, 8, and 10.

Implants were placed using the standard protocol advocated by Brånemark,² with the exception that midline crestal full-thickness mucoperiosteal flaps were used. In patients with fresh extraction sockets, an alveolectomy was performed to eliminate residual root defects. In some patients, the preparation of implant sites eliminated extraction sockets. All implants mesial to the mental foramen were 10 mm or longer, and bicortical engagement was achieved in all patients. Where implants were immediately loaded, sites were tapped 2 mm short of the apical area, and the implant was self-tapped to its final position to ensure initial stability. In patients 2, 3, 4, 5, and 8, distal implants were 7 mm in length and were placed into minimal bone over or just slightly distal to the mental foramina. In addition, these implants were placed lingual to the ridge crest to avoid trauma to the mandibular neurovascular bundle. For patient 7, the distal implant was 10 mm in length and was placed into the second molar region. It should be emphasized that these distal sites had implants placed into them without pretapping and with minimal countersinking (1 mm or less). All implants were noted to be immobile at placement. For those implants that were immediately loaded with fixed provisional prostheses, standard abutments were placed so that they would be at or 1 mm above the

tissue level. Cover screws were placed on submerged implants. Tissues were approximated using 3-0 silk sutures (Ethicon, Somerville, NJ) (Fig 2).

Fixed provisional prostheses were immediately placed on exposed implants. Preimplant dentures or fixed provisional partial dentures were converted to fixed provisional prostheses (Figs 2 and 3). In patients 1 through 9, 4-mm gold cylinders and, more recently, in patient 10 temporary cylinders (both manufactured by Nobel Biocare, Westmont, IL) were used in the fixed provisional prostheses. To accomplish the conversion, healing caps were initially placed on exposed abutments using a small amount of Pressure Indicator Paste (PIP) (Mizzy, Cherry Hill, NJ) on their occlusal aspect.

Implant positions were then registered by transferring PIP to the denture. The tissue-supported posterior denture base was used to help determine the correct positioning of the prosthesis over the implants. The portion of the prosthesis overlying healing caps was then reduced and relined, either with Perm Reline and Repair Resin (Hygienic, Akron, OH) or with Temporary Bridge Resin (L. D. Caulk Division, Dentsply, Milford, DE). The final set, of acrylic resin, was extraoral to avoid the transfer of heat of polymerization to the implants. An opening was made in the prosthesis at each abutment site, and gold or temporary cylinders were luted to the prosthesis intraorally with autopolymerizing acrylic resin. Each cylinder was polymerized individually to ensure passive fit of the provisional prosthesis to the implant abutments.

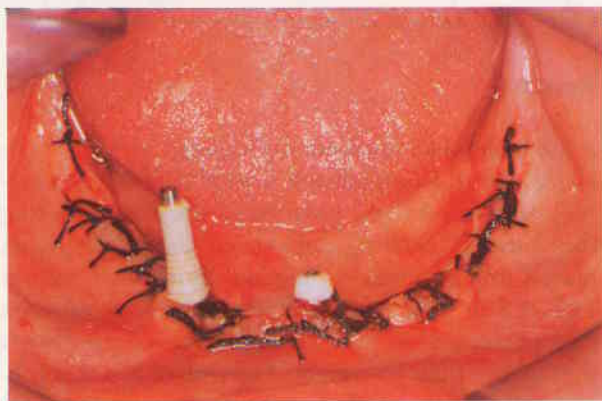


Fig 2 Tissues are sutured and a right temporary cylinder and guide pin is placed in preparation for intraoral luting and conversion of the provisional complete denture to the fixed detachable provisional prosthesis. The midline healing cap and the left standard abutment (at the tissue level) act to register the prosthesis shown in Fig 3 during the conversion procedure.

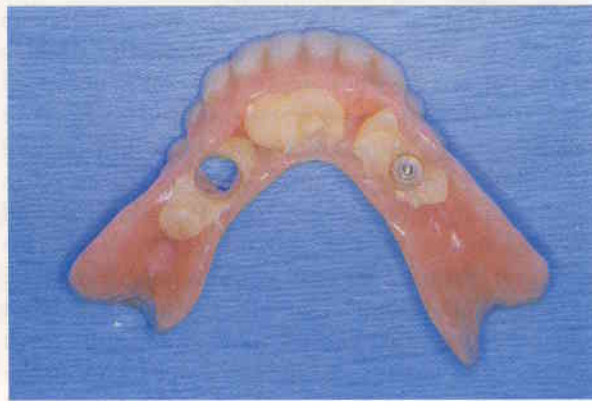

Fig 3 Acrylic resin over the right implant has been removed in preparation for the temporary cylinder shown in Fig 2. The location of the midline implant remains in autopolymerizing acrylic resin and the left implant area demonstrates the temporary cylinder that has been previously intraorally registered to the denture. After incorporation of three temporary cylinders into the denture, posterior denture bases are removed, rendering the converted provisional prosthesis totally implant supported.

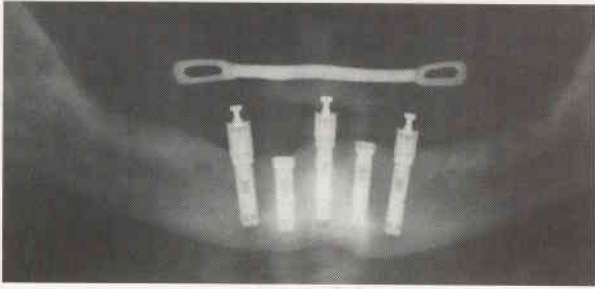


Fig 4 Radiograph of the provisional prosthesis in place, screw retained to the midline and to distal implants. The adjacent interproximal implants were submerged in the traditional fashion. The addition of a prefabricated lingual bar to the prosthesis provides rigidity and strength for the cantilevered segments of the 12-tooth provisional prosthesis, which extends distally to include the first molar.

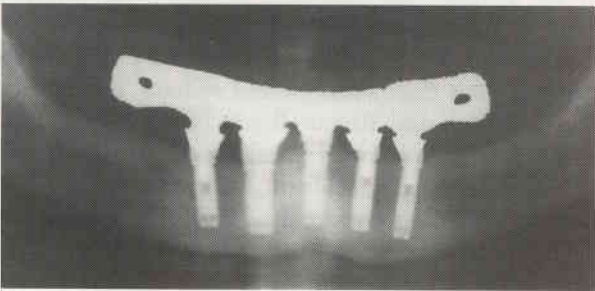


Fig 6a Postprosthesis placement radiograph of patient 10 showing all five implants incorporated into the final prosthesis.

The provisional prosthesis was then finalized extraorally by removing denture bases and flanges and incorporating a reinforcing prefabricated stainless-steel lingual bar (OIS Orthodontics, Pompano Beach, FL) (Fig 4). A detailed illustrated protocol is described in an earlier report.⁶ Implant-supported provisional prostheses were retained using gold screws (Fig 4); in patients using both implant and natural abutments, the prosthesis was cemented to teeth with TempBond (Kerr USA, Romulus, MI) and allowed to rest on the implant healing cap. This approach was used because of the excessive mobility of natural abutments. The concern was that direct connection of immobile implants and mobile teeth could lead to excessively long cantilever forces on the implants, thus potentially overloading them.

Following the 3-month healing period, the 35 submerged implants were uncovered, and standard or healing abutments were placed (Fig 5). Definitive restorations were then completed (Figs 6a and 6b) for all patients except patient 6. This patient had a fixed provisional prosthesis placed on all implants at the time of implant placement, and the final restora-

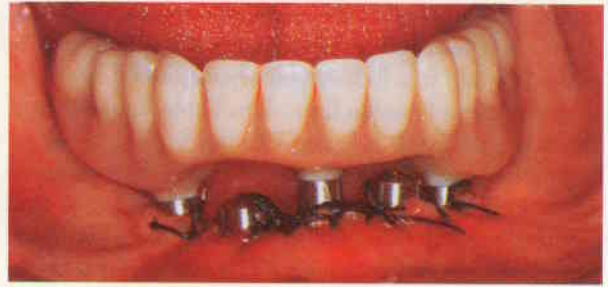

Fig 5 At second-stage surgery, healing abutments are placed on interproximal implants. The provisional prosthesis is recontoured to provide relief for healing abutments and replaced on the three immediately loaded implants.

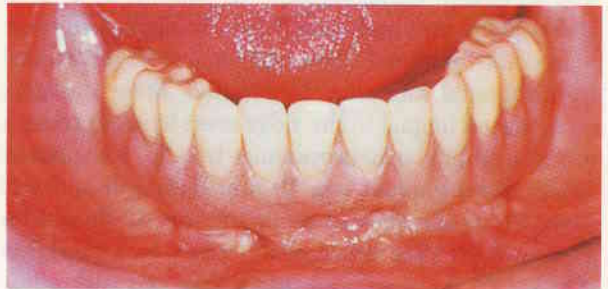

Fig 6b Clinical photograph of the final fixed detachable screw-retained prosthesis in patient 10.

tion was completed 1 month later. For patients 1, 7, and 8, the provisional prostheses were transferred to adjacent implants during second-stage surgery, at which time natural abutments also were extracted.

Results

A life table of all implants is presented in Table 1. In all patients, the immediately loaded implants successfully supported fixed provisional prostheses during the 3-month healing period. Of the 28 implants placed into immediate function, four failed, one in each of four patients (Fig 7). However, each of these four patients used their fixed provisional prostheses throughout their treatment. For patient 3, a distal 7-mm implant that failed at 21 months postimplant placement was removed uneventfully. The prosthesis was then modified, and the resulting defect was filled at the same visit with autopolymerizing acrylic resin (L.D. Caulk Division, Dentsply). In patient 5, a 7-mm implant developed mobility during the reconstructive phase and was then removed at the time of the final prosthesis placement, 5 months after

Table 1 Life Table of Immediately Loaded and Submerged Implants

	Years loaded											
	1			2	3	4	5	6	7	8	9	10
	0-3 mo	4-6 mo	7-12 mo									
Immediately loaded												
Success	28	25*	25*	24*	21*	21*	21*	19*	19*	17*	6	4
Failure		3		1								
Submerged												
Success	35	35	35	35	33	33	33	31	31	26	17	10
Failure												
Total	63	63	60	60	54	54	54	50	50	43	23	14

*Two integrated distal implants were put to sleep after final reconstruction.

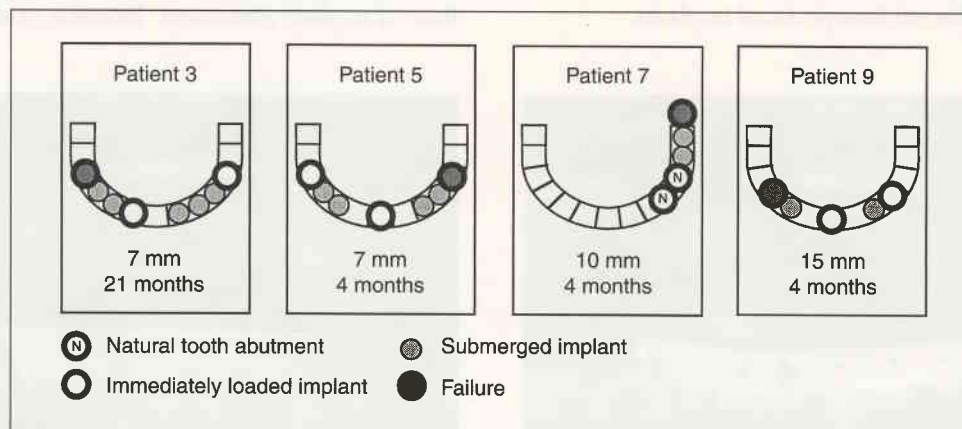


Fig 7 Analysis of failed implants. All implant failures were immediately loaded and located distal to the incisor region. One failure occurred in each of four patients (mm = length of failed implant; months = time since implant placement).

implant placement. In patient 7, a 10-mm implant was removed during abutment connection, 4 months after placement, and the fixed provisional partial denture was transferred to the adjacent, previously submerged implants. In patient 9, a 15-mm implant demonstrated mobility during abutment connection, 3.5 months after placement. Continuous service was maintained by transferring the fixed provisional prosthesis to an adjacent implant at second-stage surgery. The failed implant was replaced, and the new implant osseointegrated after a 3-month healing period. Final prosthesis fabrication was then initiated.

All 35 implants placed using the two-stage technique were integrated and are in function. Of the 25 integrated immediately loaded implants, 23 were incorporated into the final fixed prostheses, and 22 are in function. Two distal immediately loaded, osseointegrated implants in patient 4 were put to sleep by removing abutments and replacing them with cover screws. These implants remain exposed, immobile, and radiographically integrated. As previ-

Table 2 Distribution of Implant Success and Failure by Treatment

	Success	Failure
Immediately loaded (n = 28)	24	4
Submerged (n = 35)	35	0
Total (n = 63)	59	4

$P = .022$ by the log rank test.

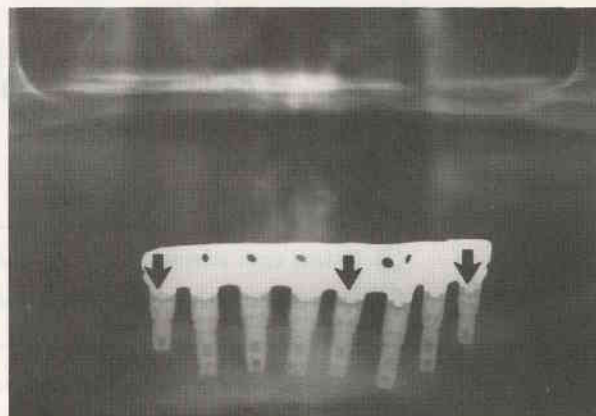
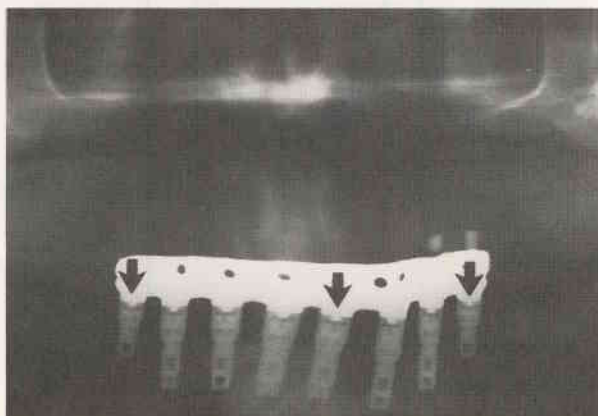
ously noted, one failed at 21 months. None of the patients in this study experienced nerve injury. Based on life-table analysis, treating the two resubmerged implants in patient 4 as losses to follow-up, the overall 10-year survival rate for all implants was 93.4%. Life-table analysis of the immediately loaded implants demonstrates a 10-year survival rate of 84.7%. Statistical analysis of submerged versus immediately loaded implants demonstrates failure rates for immediately loaded implants to be significantly higher ($P = .022$ by the log rank test; Table 2).

Figures 8 and 9 show radiographs of representative patients. Patient 2 is shown at 1.5 years after implant placement in Fig 8a and at 9 years after implant placement in Fig 8b. When comparing bone over this 7.5-year period, there is no difference between implants that were immediately loaded (as denoted by arrows) and those that were not. Patient 3 is shown at 1 year after implant placement in Fig 9a and at 8 years after implant placement in Fig 9b. This patient, a heavy smoker with exceptionally poor oral hygiene who frequently missed scheduled maintenance visits, exhibited an unusually high rate of generalized bone loss at all implants. Again, there is no apparent difference in bone change over this time period between immediately loaded and originally submerged adjacent interproximal implants.

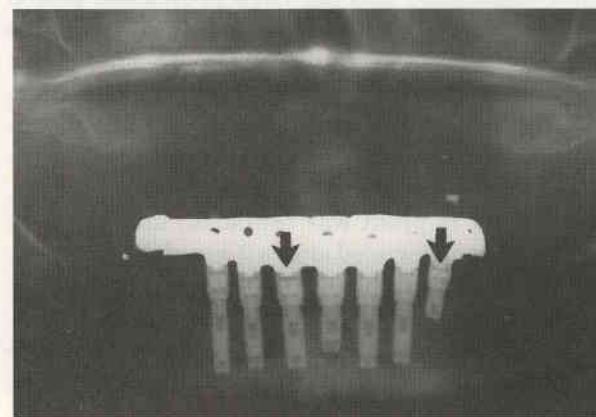
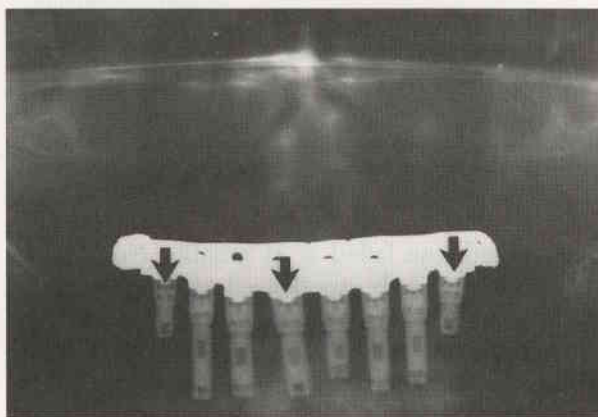
Discussion

This investigation involves a method of placing Brånemark implants into immediate function at first-stage surgery and restoring the patient with a fixed provisional prosthesis without compromising long-term reconstructive success. The study design allowed for direct comparison of implant survival and radiographic results within the same patients, between immediately loaded Brånemark implants and implants that were allowed to heal according to the standard Brånemark protocol.²

Currently, there is much interest and discussion regarding the efficacy of placing cylindrical implants in a single surgical phase and loading them at the time of implant placement. Ericsson et al⁷ compared



Figs 8a and 8b Postprosthesis placement radiographs of patient 2 at 1.5 years after implant placement (*left*) and at 9 years after implant placement (*right*). No difference can be perceived in bone levels over this time period when comparing immediately loaded implants (*arrows*) with originally submerged adjacent interproximal implants.



Figs 9a and 9b Radiographs of patient 3 at 1 year after implant placement (*left*) and at 8 years after implant placement (*right*). This patient, who practiced poor home care and made only infrequent recall visits, sustained significant bone change at all implants. However, there is no apparent difference in bone change over this time period between immediately loaded and originally submerged adjacent interproximal implants. This patient experienced a distal immediately loaded implant failure in the right posterior area.

submerged and nonsubmerged implants using a split-mouth design; they achieved similar results for both types of implants. Bernard et al⁸ reported preliminary results after placing Brånemark implants in a single surgical phase, allowing them to heal for 3 months, and then restoring them using overdentures. Their results were similar to those reported for the traditional two-stage technique. Henry and Rosenberg⁹ reported 2-year results using a single-stage surgical technique in conjunction with controlled immediate loading. In that study, of the six implants that were placed in each patient, two were submerged and four were immediately loaded using provisional removable overdentures. Fixed permanent prostheses were placed 7 to 9 weeks after implant placement. One tooth was added bilaterally to the cantilevered sections at 1-year follow-up visits. The authors suggested that clinical performance and prognosis of the procedure compared favorably with traditional methods of allowing implants to remain submerged for a healing period between placement and abutment connection. Recently, Tarnow et al reported 1- to 5-year data on immediate loading of threaded implants at stage-one surgery.¹⁰ A minimum of 10 implants, 10 mm or more in length, were placed in one edentulous arch in each of 10 patients. In the early patients, at least 5 implants, and later as many as 10 implants, were loaded immediately with a fixed provisional prosthesis. Based on their results, they concluded that immediate loading of multiple implants rigidly splinted around a completely edentulous arch can be a viable treatment modality.

Factors associated with the survival of immediately loaded implants are intimacy of initial fit, percentage of implants in contact with bone cortex, density of the cortical bone, and elimination of micromovement during the bone-remodeling period.

In our experience, those implants loaded at the time of placement must intimately engage dense cortical bone both at their apical and crestal aspect, and they must exhibit primary stability as well. These criteria are easily met in the anterior mandible. The zone of the jaw, between the mental foramina, is considered to have the greatest density and best bone quality. Within this region, the symphysis provides the most trabecular density. The areas just anterior to the mental foramina are generally less dense, and the area of the lateral incisors are less dense still and often hollow. However, this entire region features thick dense cortical plates, which allow for engagement of the crest, as well as dense trabecular bone or opposing cortex at the inferior border, unlike the anatomy found in the posterior mandible and maxilla.

The authors consider the use of threaded implants to be an important factor in the success of this tech-

nique, since they allow for immediate mechanical engagement of bone. The approach used here of allowing standard implants to entirely self-tap in posterior sites, and for the apical 2-mm segment to self-tap in anterior intraforaminal sites, provided additional immediate stabilization. The design of the occlusal aspect of the standard 3.75-mm Brånemark implant and the use of limited countersinking may have been important elements in the effectiveness of this procedure. It appears that the horizontal ledge, below the platform of the implant head, provides a stabilizing base against dense crestal cortical bone.

Results of this study also suggest that bone remodeling probably does not occur all at once over the entire implant. Otherwise, mobility would have been expected to develop during the osseous remodeling process. Rather, it appears that remodeling is probably variable, with osteoclastic and osteoblastic activity balanced, so that a stable implant is always maintained during osseointegration.

In this patient population, the potential for micromovement was minimized by rigidly splinting implants together with the screw-retained, passive-fitting fixed provisional prostheses. These prostheses were rarely, if ever, removed, to minimize the potential for micromovement during the healing period. Prostheses supported by teeth and implants were cemented to teeth, and they simply rested on the implant for vertical support.

The technique described in this paper minimized patient management problems and increased patients' acceptance of implant treatment. Although the failure rate among immediately loaded implants was found to be higher, no implants failed during the initial 3-month healing phase. Therefore, for the purpose of supporting fixed provisional prostheses, this method has been successful. Submerging some implants for a traditional period of healing provided a backup for implants that had been placed into immediate function and subsequently failed to integrate. It is encouraging that under controlled conditions, in selected patients, implants can be loaded at the time of implant placement without compromising the long-term outcome. In a few instances, immediately loaded implants failed prematurely, but continuous fixed-prosthesis function was easily maintained. Adjacent implants that were submerged and allowed to osseointegrate in the usual fashion were brought into function by incorporating them into the fixed provisional prosthesis at the time of second-stage surgery.

The use of only three implants, one in the symphysis and two in the posterior region, has proven effective in supporting a 12-unit, implant-supported, screw-retained prosthesis. It has been hypothesized

that the key to the success of this configuration lies in the creation of a broad-based supportive implant-abutment tripod. In the early patients, eight implants were used. Five of the implants were submerged and three employed as immediate abutment supports. This approach proved too costly and complex.

Over time, confidence in the technique of immediately loading implants has increased. The difficulties of implant placement, the cost of including so many implants in the final restoration, and the risk of complications to the neurovascular bundle have resulted in modifications to the technique. Currently, five implants placed anterior to the mental foramina are used. The midline implant and two posterior implants serve as immediate abutments in creating a broad-based triangle of support. The submerged implants in the lateral incisor sites provide predictable back-up, should one or more of the immediately loaded implants fail and require replacement. Experience has shown that a 12-unit provisional prosthesis can be fabricated more easily when the two distal abutments are mesial to the foramina than they could in the earlier approach when they were placed distally. The cantilever lengths extend to the first molar and occlusal force is normal; however, a rigid bar must be incorporated into the fixed provisional prosthesis to minimize fracture of the cantilevered segments. Furthermore, the adjacent submerged implants are no longer incorporated into the provisional prosthesis at the time of second-stage surgery (see Fig 5). Instead, the prosthesis is supported only by the immediately loaded implants during the definitive restorative procedures. Based on this experience of not losing a midline implant and only rarely losing a distal implant, the treatment strategy maximizes a successful outcome while reducing complexity and cost.

Since no bone was available for placement of distal implants over the mental foramina in patient 6, all implants were immediately loaded. This approach is less predictable and, in the event of failure, might have presented significant complications. Though unlikely, failure of several implants in this patient could have required an extended healing and implant-replacement period. This approach is not currently recommended; rather, the previously described five-implant (three immediate, two delayed) strategy is preferred.

Three of the four failures occurred distal to the mental foramina, and these results correlate with the historical increase in failure rates for implants in these regions.¹¹ Based on these data involving such a small number of failures, it is not possible to draw firm conclusions regarding the effect of site on immediate loading.

Two of the implants that failed were 7 mm in length and two others were 10 mm and 15 mm, respectively. While implant length may be a factor in survival, it does not appear to be as critical as are bone quality and intimacy of initial fit and stability. In the future, wider-diameter implants may improve stability for these techniques in lower-density bone.

In these studies, threaded implants were immediately loaded in the mandible only. Readers are cautioned not to extrapolate these results to the maxilla, especially to the posterior region, where bone quality and quantity differ more dramatically. Additional research needs to be done to provide alternatives in situations where problems of poor bone quality must be overcome.

This study provides evidence for the potential of reducing the number of implants that might be necessary to support a full-arch fixed detachable mandibular prosthesis. These results suggest that three implants arranged in a broad-based triangular pattern may provide adequate support in certain patients. The long-term efficacy of such minimal support must be further evaluated. However, the concept opens intriguing treatment-planning possibilities.

Conclusion

On the basis of these results, mandibular implants can be confidently placed into immediate function at the time of implant placement, to provide adequate support for fixed provisional prostheses during 3-month healing periods, while adjacent submerged implants are allowed to osseointegrate. However, treatment plans should account for possible failure of those implants placed into immediate function. In particular, immediately loaded implants placed distal to the incisor region appear to be susceptible to failure.

References

1. Schnitman PA, Shulman LB (eds). *Dental Implants: Benefit and Risk*. US Dept Health and Human Services, publication 81-1531. Government Printing Office, 1980.
2. Adell R, Lekholm U, Rockler B. A 15-year study of osseointegrated implants in the treatment of the edentulous jaw. *J Oral Surg* 1981;10:387-416.
3. Brånemark P-I, Hansson BO, Adell R, Breine U, Lindström J, Hallen O, Öhman, A. Osseointegrated implants in the treatment of the edentulous jaw. Experience from a 10-year period. *Scand J Plast Reconstr Surg* 1977;11(suppl 16):1-132.
4. Babbush CA, Kent N, Misiek DJ. Titanium plasma-sprayed (TPS) screw implants for the reconstruction of the edentulous mandible. *J Oral Maxillofac Surg* 1986;44:274-282.
5. Buser D, Schroeder A, Sutter F, Lang NP. The new concept of ITI hollow-cylinder and hollow-screw implants: Part 2. Clinical aspects, indications, and early clinical results. *Int J Oral Maxillofac Implants* 1988;3:173-181.

6. Schnitman PA, Wöhrle PS, Rubenstein JE. Immediate fixed interim prostheses supported by two-stage threaded implants: Methodology and results. *J Oral Implantol* 1990;16:96-105.
7. Ericsson I, Randow K, Glantz P-O, Lindhe J, Nilner K. Clinical and radiographical features of submerged and non-submerged titanium implants. *Clin Oral Implants Res* 1994;5:185-189.
8. Bernard J-P, Belser UC, Martinet J-P, Borgis SA. Osseointegration of Branemark fixtures using a single-step operating technique. *Clin Oral Implants Res* 1995;6:122-129.
9. Henry P, Rosenberg I. Single-stage surgery for rehabilitation of the mandible: Preliminary results. *Pract Periodontics Aesthet Dent* 1994;6:15-22.
10. Tarnow DP, Emtiaz S, Classi A. Immediate loading of threaded implants at stage 1 surgery in edentulous arches: Ten consecutive case reports with 1- to 5-year data. *Int J Oral Maxillofac Implants* 1997;12:319-324.
11. Schnitman PA, Rubenstein JE, Wöhrle PS, DaSilva JD, Koch GC. Implants for partial edentulism. *J Dent Educ* 1988;52:725-736.