

# Notes

Eastern Oklahoma Periodontics

Fall 2014

Kelly Professional Building • 6565 South Yale Ave., Ste. 1008 • Tulsa, Oklahoma 74136 • 918.492.0737 • www.eoperiodontics.com

## Fall Is Here!

Fall is here, and we are excited at what this season brings! First of all there is football. We are very proud of Tress Way making the team, and he is now the punter for the Washington Redskins. Tress is the son of our hygienist Deb Way. Deb has worked with us for 20 years and for the last 12 years she has worked as a hygienist. Her son Cole has also just signed to be a pitcher for the Kansas City Royal's organization.

Second, CAD CAM technology is continuing to play a big part in implant therapy. The first case presentation shows CAD CAM abutments being utilized to restore two anterior implants. Custom milled abutments provide superior esthetics on your final restorations, and can greatly help prevent the incidence of sub-gingival cement. The case uses Zirconia



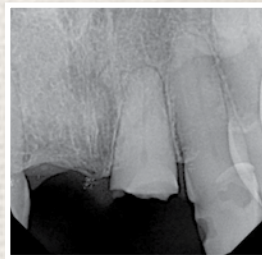
Atlantis abutments. I do think in aesthetically demanding situations it is OK to use Zirconia, but in general, titanium or gold hue titanium is by far the material of choice. Peri-implantitis is also unfortunately a growing concern. The wrong abutment choice can set you up for failure. Having a customized choice for your patient can help decrease the incidence of problems.



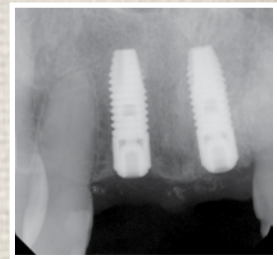
# Case Studies

**Case study #1:** The patient was missing tooth #8. Tooth #9 was fractured and deemed non restorable. Tooth #9 was extracted and an immediate implant was placed, and an implant was also placed in the #8 area. After the implants had healed, they were restored with Atlantis CAD CAM abutments, and all porcelain crowns.

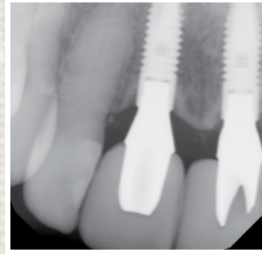
**Case study #2:** The patient had significant recession from tooth #21 to tooth #27. Several of the teeth also had mucogingival defects. The patient had subepithelial connective tissue grafting, with her tissue, from tooth #21 to tooth #27. As you can see, she now has thick healthy gingiva and a wide zone of keratinized attached gingiva on all of the grafted teeth. Significant root coverage was also achieved, including #27, where a portion of a buccal composite restoration was removed.



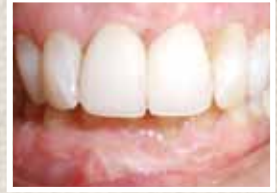Pre-Op



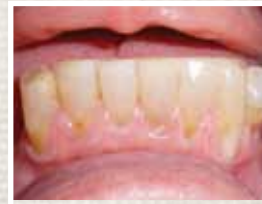Post-Op



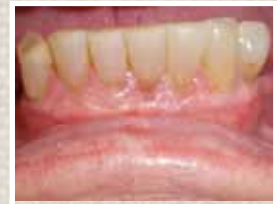Post-Op



Post-Op



Pre-Op



Post-Op

## Services Offered By Eastern Oklahoma Periodontics

- Implant placement
- Hard and soft tissue grafting  
*which includes implant site preparation*
- Cosmetic periodontics
- Treatment of periodontal disease

*Dr. William B. Wynn, IV*



Eastern Oklahoma  
Periodontics  
6565 South Yale Ave. Ste. 1008  
Tulsa, OK 74136

