

# Notes

Eastern Oklahoma Periodontics

Summer 2014

Kelly Professional Building • 6565 South Yale Ave., Ste. 1008 • Tulsa, Oklahoma 74136 • 918.492.0737 • www.eoperiodontics.com

## Summer Time

Summer is in full swing, and so is Eastern Oklahoma Periodontics! We are seeing great results with our new implant system, the Astra Tech EV. From a prosthetic stand point, the restorative platform is much more user friendly than the TX. It is much easier to seat the impression posts and abutments. The new 5.4 diameter implant is also working very well in large molar areas. We are continuing see the great bone stability that we have always seen with Astra's conical connection. Conical connections are where much of the industry is going. Micro-movement at the implant abutment interface makes for a perfect bacteria pump during function. Conical abutment connections, like Astra Tech, help reduce the movement, hence one of the reasons we are seeing such stable bone levels!



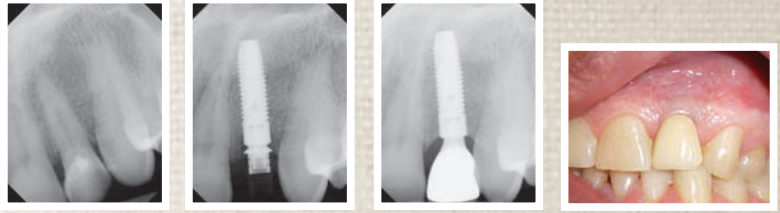
The new ASTRA TECH Implant System™ EV



# Case Studies

Case 1: Tooth #10 was fractured and non-restorable. I extracted #10 and performed immediate implant placement. I also immediately placed a temporary. The implant was restored with a custom abutment and crown. One year post op radiograph shows excellent bone levels and stable tissue contours.

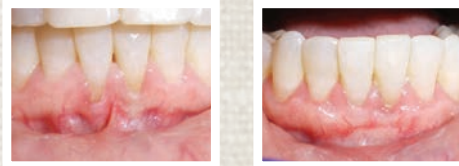Case #1



Pre Op Post Op

Case 2: Recession and mucogingival defects on the buccal of tooth #24 and #25 with a marked frenum. A sub-epithelial connective tissue graft was performed on #24 and #25. Post op results show removal of the frenum, excellent root coverage, and a wide zone of keratinized attached gingiva.

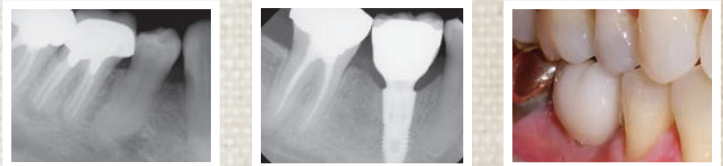
Case #2



Pre Op Pre Op

Case 3: Tooth #30 presented with a vertical root fracture. It was extracted and socket preservation therapy was performed. Once the socket healed, implant placement was performed. The implant was restored with a custom milled titanium abutment and crown.

Case #3



Pre Op Post Op

## Services Offered By Eastern Oklahoma Periodontics

- Implant placement
- Hard and soft tissue grafting  
*which includes implant site preparation*
- Cosmetic periodontics
- Treatment of periodontal disease

*Dr. William B. Wynn, IV*



Eastern Oklahoma Periodontics

6565 South Yale Ave. Ste. 1008  
Tulsa, OK 74136