

Notes

Eastern Oklahoma Periodontics

Winter 2013

Kelly Professional Building • 6565 South Yale Ave., Ste. 1008 • Tulsa, Oklahoma 74136 • 918.492.0737 • www.eoperiodontics.com

A New Year

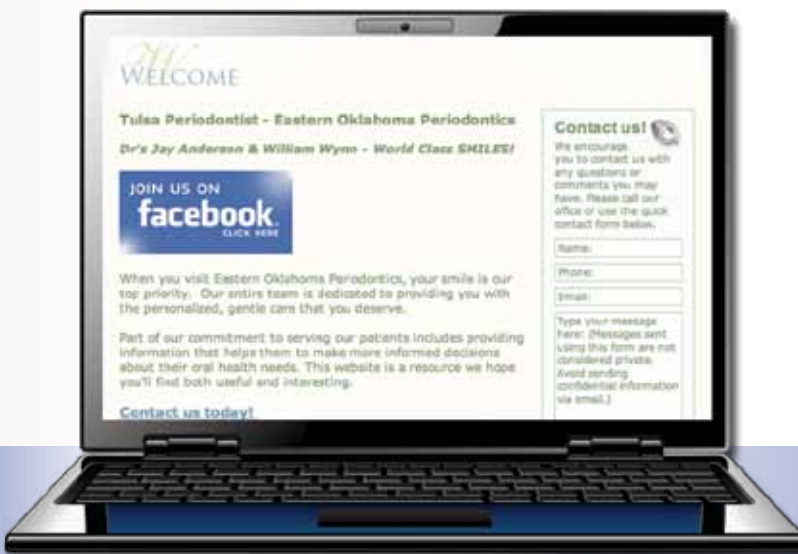Well, 2013 is upon us. We had a great 2012 at Eastern Oklahoma Periodontics, and we are looking at having an even better 2013.

If you have not ever worked with our office before, I encourage you to give us a try! I have been practicing in Tulsa now for over ten years. My staff is second to none. They are all true professionals, and I can promise you that your patients will be well taken care of.



Social media has become a bigger part of our lives. That rings true for our practice as well. Please “like” our practice on Facebook. We are listed as Eastern Oklahoma Periodontics. I periodically post cases that I have done, links to articles that pertain to dentistry and links to our latest newsletters!

People ask me what insurance plans we are on. At this time, I am not a “preferred provider” on any of the plans. We will file insurance for your patients, but as an out of network provider. I can guarantee you that if we do treat your patient, that my staff and I will give 110% to make sure that they have a fantastic outcome and a “wow” experience.



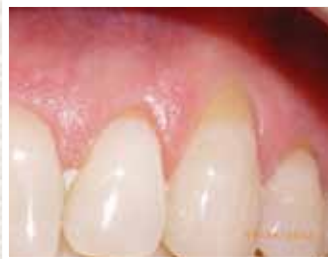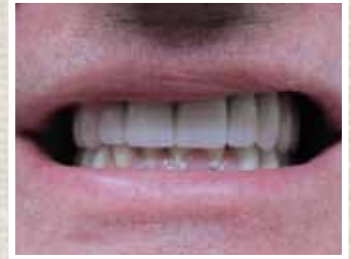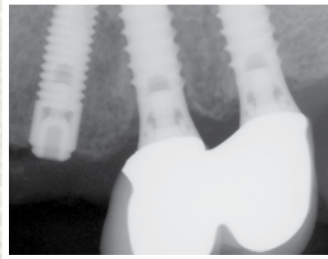
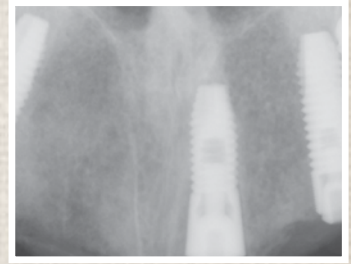
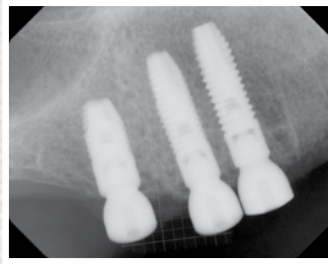
Follow Us On Facebook

You can link to our page from our website, www.eoperiodontics.com.

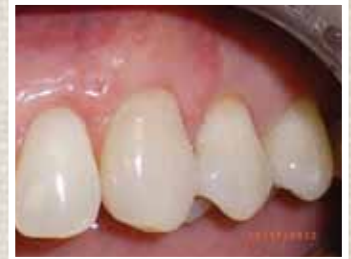Case Studies

Case study #1: I had placed implants in the past in the #12 and #13 areas. The patient now had only a few remaining natural teeth, significant bridge work, and non-restorable teeth. Tooth #'s 5, 7, and 9 were extracted and implants were placed in the #4, 6, 9, and 11 areas. An implant was later placed in the #5 area after initial healing. The case was restored with Atlantis custom abutments and a cement retained bridge.

Case study #2: Patient presented with gingival recession on tooth #'s 10 and 11. A subepithelial connective tissue graft was performed. Excellent root coverage was achieved!



Pre-Op



Post-Op



Services Offered By Eastern Oklahoma Periodontics

- Implant placement
- Hard and soft tissue grafting
which includes implant site preparation
- Cosmetic periodontics
- Treatment of periodontal disease

Dr. William B. Wynn, IV



Eastern Oklahoma
Periodontics
6565 South Yale Ave. Ste. 1008
Tulsa, OK 74136

