

# Notes

Eastern Oklahoma Periodontics

Winter 2014

Kelly Professional Building • 6565 South Yale Ave., Ste. 1008 • Tulsa, Oklahoma 74136 • 918.492.0737 • [www.eoperiodontics.com](http://www.eoperiodontics.com)

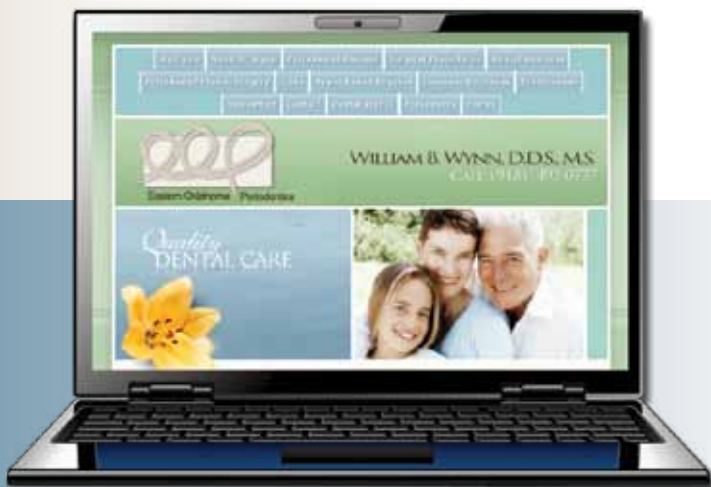## A New Year

Winter and the New Year are here. Last year was a very blessed year for Eastern Oklahoma Periodontics and we are even more excited about 2014! This is actually our nineteenth edition of Eastern Oklahoma Periodontics Notes. I hope you have been enjoying them. One thing I am excited about this year is that I have been elected Vice President of the Oklahoma Dental Foundation. The foundation has been doing great things with the Mobile Smiles program. Please consider either volunteering or making a contribution. The need is very great. You can call toll free at (888) 241-1253 for more information.



In the world of periodontics, the field of dental implantology continues to be a very large part of our practice. The technology now is really amazing. The biggest improvement we have made in our practice is switching to an implant with a conical connection. Without a tight connection between the implant and the abutment, you basically create a bacteria pump every time the patient bites down. That movement of bacteria at the implant/abutment interface will cause inflammation and bone loss over time.

Having the proper connection will help your patients have a stable and healthy implant over time.

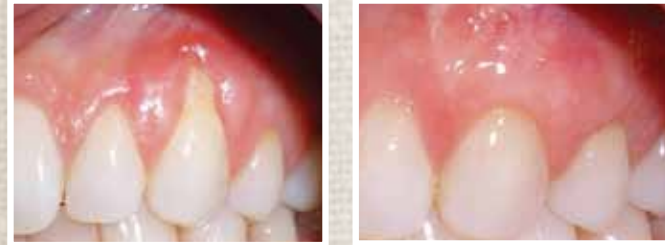

*Please visit our website. There is useful information for both patients and dentists.*

*[www.eoperiodontics.com](http://www.eoperiodontics.com)*

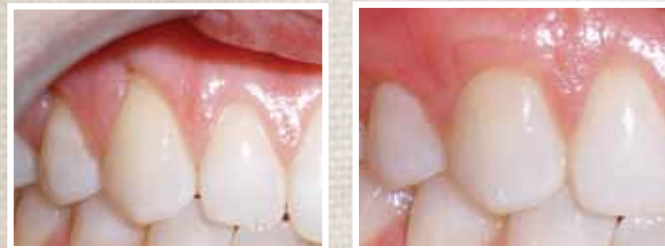# Case Studies

**Case study #1:** The patient presented with severe recession in the maxillary arch. Sub-epithelial connective tissue grafts were performed in the maxillary right and maxillary left quadrants. As you can see we got an excellent functional and esthetic result!

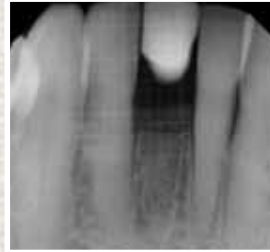


Pre-Op

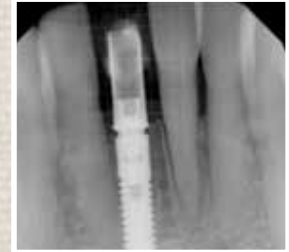Post-Op



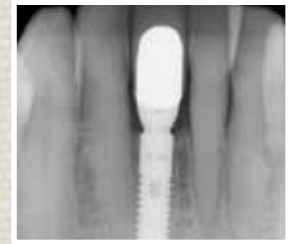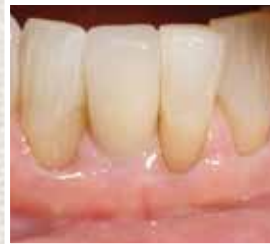**Case study #2:** Patient had to have a lower right central incisor extracted. An Astra Tech dental implant was placed and the implant was immediately temporized. Once the implant had healed it was restored with an Atlantis custom abutment.



Pre-Op



Post-Op



## Services Offered By Eastern Oklahoma Periodontics

- Implant placement
- Hard and soft tissue grafting  
*which includes implant site preparation*
- Cosmetic periodontics
- Treatment of periodontal disease

*Dr. William B. Wynn, IV*



Eastern Oklahoma  
Periodontics  
6565 South Yale Ave. Ste. 1008  
Tulsa, OK 74136

