

Notes

Eastern Oklahoma Periodontics

Spring 2010

Kelly Professional Building • 6565 South Yale Ave., Ste. 1008 • Tulsa, Oklahoma 74136 • 918.492.0737 • www.eoperiodontics.com

The Technology Upgrades Continue

Just in the last year Eastern Oklahoma Periodontics has made huge investments in new technology to provide the best care for your patients. We have recently added a new soft tissue laser to our surgical armamentarium. Look for even more new additions in the coming months.

We have also added a new small diameter implant for over denture cases for patients with very thin ridges. We believe this will enable us to provide treatment to patients that may have not been candidates in the past. The new system has an ERA attachment, which has a proven track record.

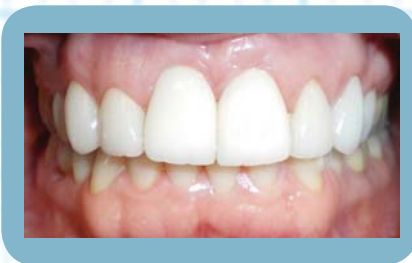More Choices

We have expanded the line of implant systems currently offered in our office. We are currently placing Nobel Biocare, Zimmer, Straumann, and Blue Sky Bio.



Case Studies: Cosmetic Implants

Case #1

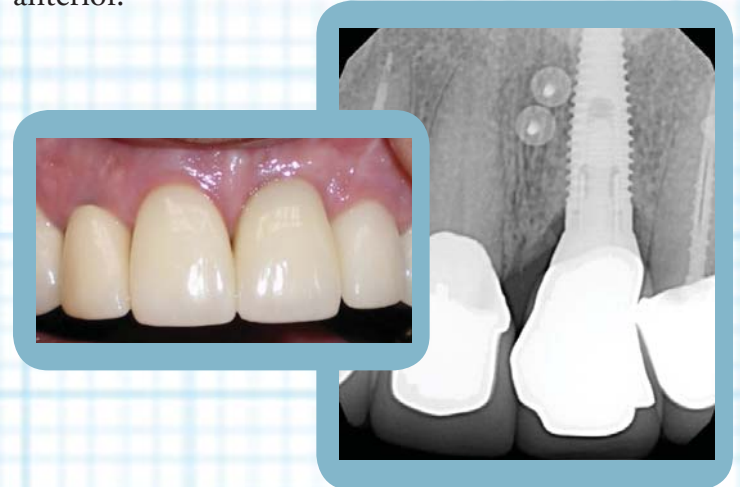


At Eastern Oklahoma Periodontics, we take pride in our results for cosmetic implant cases.

Utilizing zirconia abutment technology and new implant surface technology we are doing several immediate extraction, immediate placement, and immediate temporization cases. In this case tooth numbers 8 and 9 were extracted. Immediate implants were placed. Permanent zirconia abutments were placed, and the patient went to her general dentist for temporization. The case was eventually restored with all porcelain crowns. The patient never went without her teeth!

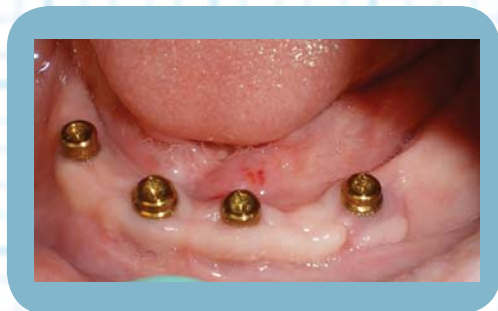Case #2

This case was not an immediate load case, but shows the kind of results we are getting in the anterior.

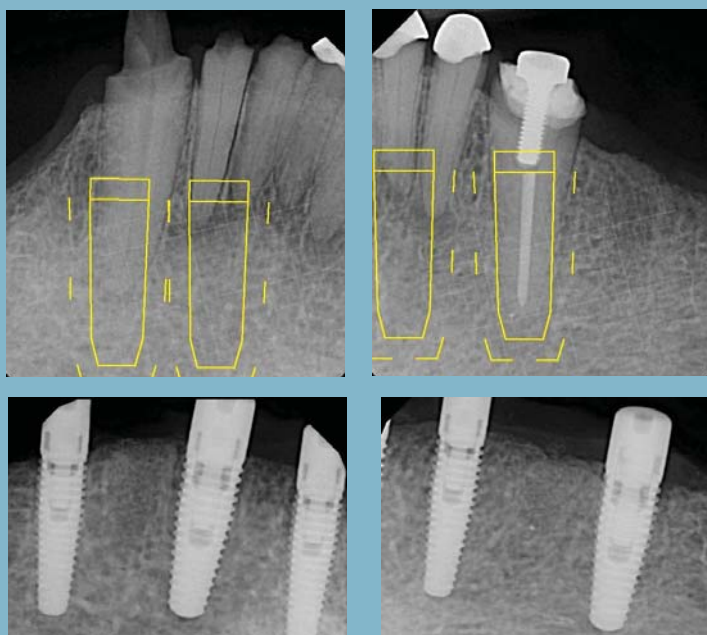


Case #3

The patient came in with a hopeless prognosis on all the remaining mandibular dentition. The patient was already edentulous on the maxillary arch and was wearing a maxillary denture. In this patient's case I extracted all of the mandibular teeth, performed immediate implant placement, and delivered the mandibular immediate denture for the general dentist. The implants were loaded 4 months post extraction. I did have to do a free gingival graft in the #22 area to augment the attached gingiva in that area. Locator abutments were utilized in this case.



Pre-Op



Services Offered By Eastern Oklahoma Periodontics

- Implant placement
- Hard and soft tissue grafting
which includes implant site preparation
- Cosmetic periodontics
- Treatment of periodontal disease

Dr. William B. Wynn, IV



Eastern Oklahoma Periodontics

6565 South Yale Ave. Ste. 1008
Tulsa, OK 74136