

Notes


Eastern Oklahoma Periodontics

Summer 2010

Kelly Professional Building • 6565 South Yale Ave., Ste. 1008 • Tulsa, Oklahoma 74136 • 918.492.0737 • www.eoperiodontics.com

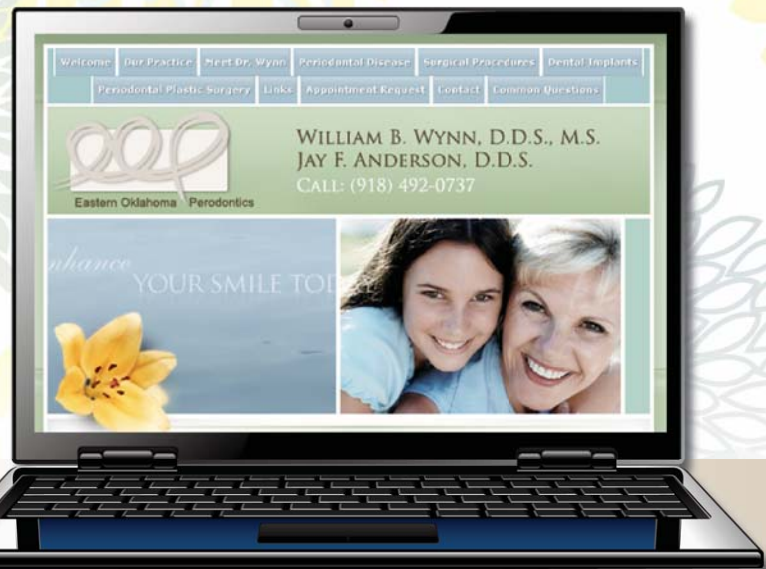Thank You

I hope all of you are enjoying a great summer. As you can see, Ava and Catherine are growing up fast. They both are good swimmers, and we all have really been enjoying these warm summer months. I just want to also take this time to say thank you to all of our referring doctors, dental hygienists, and their staffs! We have been very blessed to have the opportunity to treat your patients. We also feel very blessed to work with such great referrals!



Perio Tip

Host response is pretty much the dominant topic in the treatment of periodontal disease at this time. Bacteria may initiate the response, but it is the host response that is doing the damage. Currently low dose Doxycycline is a great adjunct to treat inflammation systemically. The current recommended dose is 20mg, twice a day. The dosage is crucial, because higher doses start killing bacteria and this contributes to antibiotic resistance. In our experience, you will not notice a change in tissue character until the patient has been on the medication for at least 3 months!



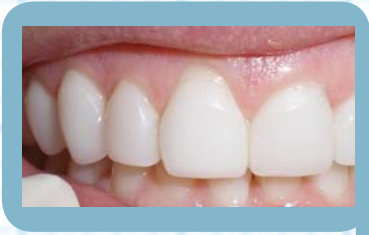Please visit our website. There is useful information for both patients and dentists.

www.eoperiodontics.com

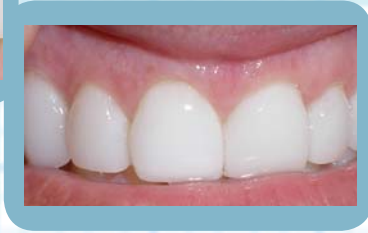Case Studies

Subepithelial Connective Tissue Graft:

This I felt was such a great case because it shows how you can get a dramatic, stable result, with pretty much no scarring or evidence of periodontal surgery. The patient had anterior Lumineers. The patient began to get some gingival recession on tooth #8. A pouch graft was done utilizing connective tissue from the palate. Healing was uneventful, and excellent root coverage was achieved.



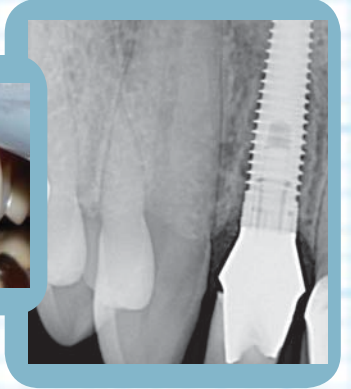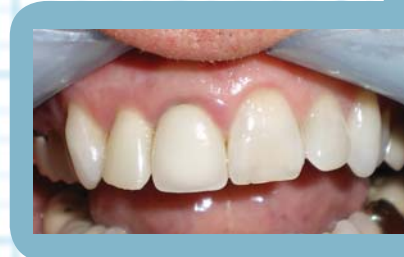Before



After

Immediate implant placement of tooth #7:

Tooth #7 was extracted and an immediate implant was placed. A Zirconia abutment was placed and a custom temporary was cemented. The temporary was adjusted so that it was out of occlusion. These pictures show the case 4 months post surgery. The patient is on their way to their general dentist's office for a standard crown and bridge impression for an all porcelain crown.



Services Offered By Eastern Oklahoma Periodontics

- Implant placement
- Hard and soft tissue grafting
which includes implant site preparation
- Cosmetic periodontics
- Treatment of periodontal disease

Dr. William B. Wynn, IV



Eastern Oklahoma Periodontics

6565 South Yale Ave. Ste. 1008
Tulsa, OK 74136