

Notes

Eastern Oklahoma Periodontics

Winter 2010

Kelly Professional Building • 6565 South Yale Ave., Ste. 1008 • Tulsa, Oklahoma 74136 • 918.492.0737 • www.eoperiodontics.com

Dr. Anderson's Farewell

I have practiced in the same location since arriving in Tulsa, May 1976, 34 years ago and I have thoroughly enjoyed my practice, co-workers, patients, and my professional relationships.

Tulsa has been good to me, my family and my practice. I am not leaving town but I am retiring from practice. I can do this comfortably and with great joy knowing that Eastern Oklahoma Periodontics, our employees, patients, and you will be well supported by Dr. Bernie Wynn.


It has now been eight years since Bernie joined Eastern Oklahoma Periodontics. He is past President Tulsa Endo Study Club and current President of Tulsa County Dental Society. I can confidently leave our patients in his care.

I have worked on many of your families, friends, and of course your patients. I want to thank you for your support, trust and confidence.

My bucket list is overflowing and I have many new paths to follow. Call me for breakfast, lunch, dinner, and fishing reports.

Sincerely,

Jay F. Anderson, DDS



Case Studies

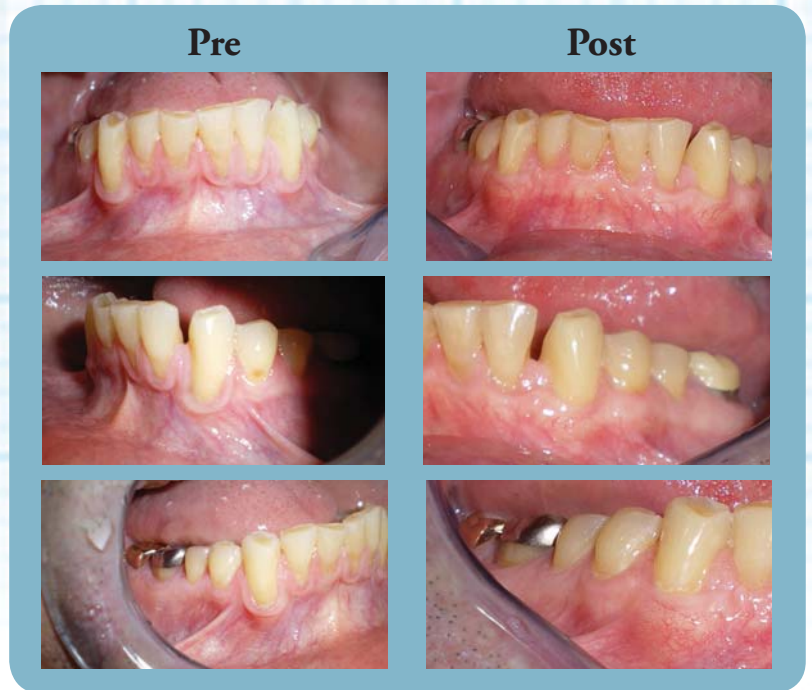Subepithelial Connective Tissue Graft:

The patient presented with severe gingival recession and muco-gingival defects from tooth #21 to tooth number #28. The patient had interproximal bone loss, so 100% root coverage was not possible.

The goals of this type of periodontal plastic surgery should include:

- 1: *Root coverage*
- 2: *Wider zone of keratinized attached gingiva*
- 3: *Increased tissue thickness.*

As you can see, all of these goals were accomplished. An added benefit of an autograph that can not be achieved with any other technique, is that genes are transferred from the palate to the donor recipient area. When these genes are expressed, the results are seen in changing the phenotype of the tissues in the donor recipient area. The recession resistant qualities of the palatal tissue is then present at the graft site.



Services Offered By Eastern Oklahoma Periodontics

- Implant placement
- Hard and soft tissue grafting
which includes implant site preparation
- Cosmetic periodontics
- Treatment of periodontal disease

Dr. William B. Wynn, IV



Eastern Oklahoma Periodontics

6565 South Yale Ave. Ste. 1008
Tulsa, OK 74136