

Notes

Eastern Oklahoma Periodontics

Fall 2009

Kelly Professional Building • 6565 South Yale Ave., Ste. 1008 • Tulsa, Oklahoma 74136 • 918.492.0737 • www.eoperiodontics.com

Fall 2009

Fall is here and it is time for your second edition of Eastern Oklahoma Periodontics Notes! In this addition we will be covering several topics: the upcoming Tulsa Oklahoma Mission of Mercy, our website (www.eoperiodontics.com), some new and exciting services being offered, and our monthly case study.

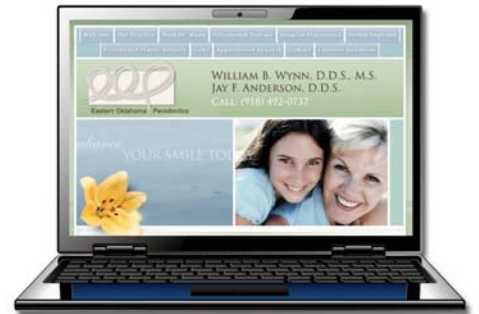Mission of Mercy

February 5-6, 2010 will be an exciting time here in Tulsa. Oklahoma will host its first Mission of Mercy at the Tulsa Convention Center. Thousands of people in need will receive free dental care. The only way this will happen is with your participation. This is a great chance for our profession to really reach out and help people. Please go to www.okmom.org and sign up to be a volunteer. Hygienists, dentists, staff, and spouses will all be needed to make this a success.



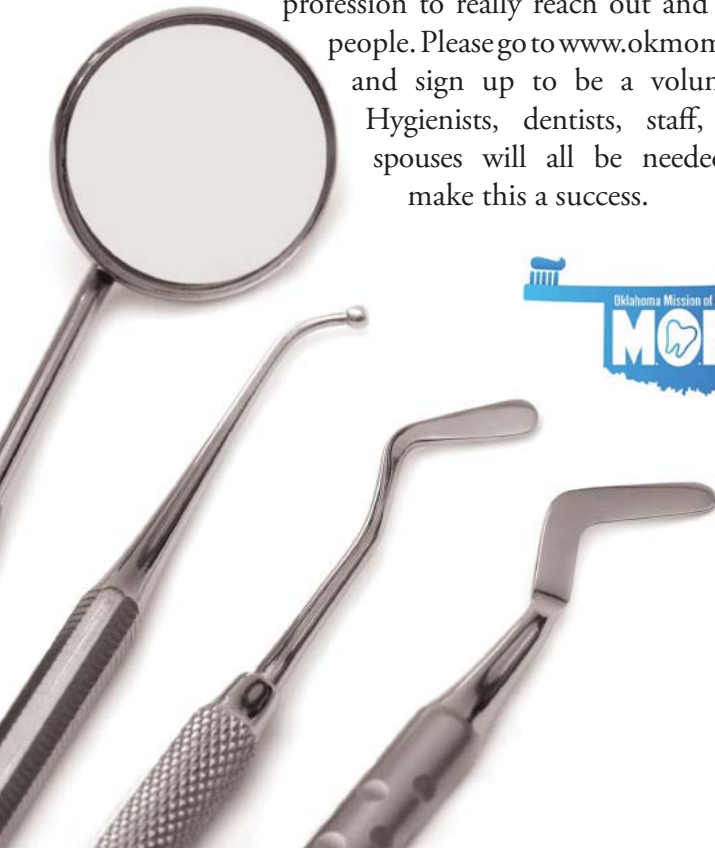Online

Our new website, www.eoperiodontics.com, has turned out to be a huge hit with both patients and doctors. Your patients can get vital information about their condition, as well as the procedures that will be used to treat it. We are also posting copies of our newsletter online to be downloaded in the .pdf format. We are also currently in the process of adding video testimonials, starting with two patients who underwent implant surgery in the mandibular arch. In both cases four implants were placed for an implant retained over denture. The videos will show just how much people's quality of life can improve with this service.



State of the Art

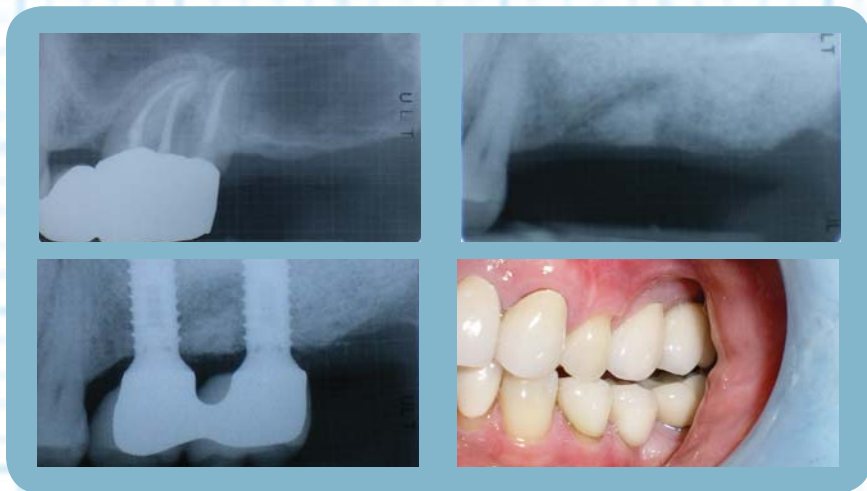
Eastern Oklahoma Periodontics has recently made a large investment in technology which we feel will help us offer state of the art treatment to your patients. All seven of our operatories are now equipped with digital x-ray capability. We went to digital radiography in May, and have already upgraded to the new Dexis Platinum sensor, which has four times the image quality as the previous sensor. This system's technology also lets us use two-dimensional implant planning with a number of pre-loaded implant specs. The software also has a bone integration module, which uses computer algorithms to estimate bone to implant contact. If we feel that three-dimensional treatment planning is necessary, we are equipped with in office CT planning software. We can work with local imaging centers for diagnostic three-dimensional images and guided surgery.



Case Studies

Sinus Augmentation:

The patient had a 3 unit fixed bridge from tooth number 12 to tooth number 14. Tooth number 14 had class III furcation involvement and was class three mobile. Tooth number 14 was extracted, and sinus augmentation was performed. After healing of the bone graft, two dental implants were placed. Once the implants had fully integrated, the patient's general dentist restored them with two fused crowns. The impression was a simple "basket" abutment level impression. The implants are now several years out, and show no signs of inflammation.



Services

Offered By Eastern Oklahoma Periodontics

Dr. William B. Wynn, IV Dr. Jay Anderson

- Implant placement
- Hard and soft tissue grafting
which includes implant site preparation
- Cosmetic periodontics
- Treatment of periodontal disease



Eastern Oklahoma Periodontics

6565 South Yale Ave. Ste. 1008
Tulsa, OK 74136