

Notes

Eastern Oklahoma Periodontics

Summer 2009

Kelly Professional Building • 6565 South Yale Ave., Ste. 1008 • Tulsa, Oklahoma 74136 • 918.492.0737 • www.eoperiodontics.com

Getting To Know Us


Dr. William B. Wynn, IV

Dr. William B. Wynn, IV is a second-generation dentist from McAlester, Oklahoma. Dr. Wynn received his B.S. from the University of Oklahoma in 1995. He went on to graduate with his D.D.S. from the University of Oklahoma College of Dentistry in 1999. Dr. Wynn then completed his residency in Periodontics and received his Masters of Science in Periodontics in 2002. Dr. Wynn maintained a 4.0 grade point average during his residency and Masters program. Upon graduation Dr. Wynn joined Eastern Oklahoma Periodontics in 2002.

Dr. Wynn is a member of the American Dental Association, the Oklahoma Dental Association, the American Academy of Periodontology, and is the current president of the Tulsa County Dental Society. Dr. Wynn and his wife Neely have two daughters, Ava, and Catherine.



Ava, Neely, Bernie and Catherine Wynn



Leigh, Jay, Nancy and Cody Anderson

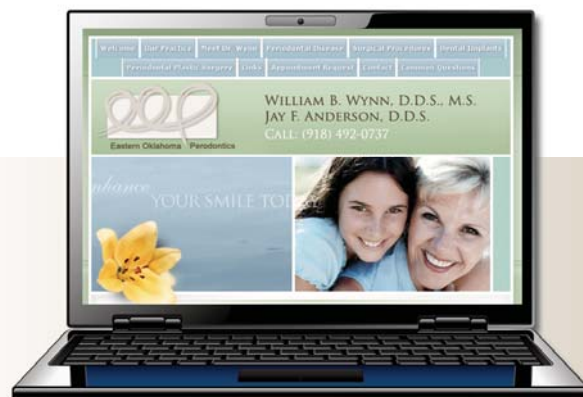Dr. Jay Anderson

Dr. Jay Anderson received his B.A. from Wichita State University. He went on to complete his D.D.S. at the University of Missouri. Dr. Anderson also completed his periodontal residency at the University of Missouri.

Dr. Anderson is a member of the American Dental Association, the Oklahoma Dental Association, the American Academy of Periodontology, and is member of the Tulsa County Dental Society.

Dr. Anderson started Eastern Oklahoma Periodontics, and has maintained his practice in the Kelly Professional Building on the Saint Francis medical campus for 33 years. Dr. Anderson and his wife Nancy have two children, Leigh and Cody.

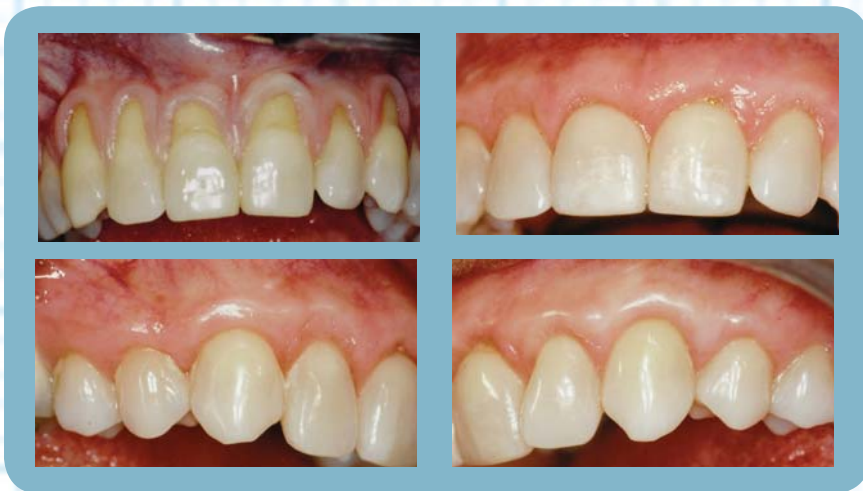Please visit our website. There is useful information for both patients and dentists.
www.eoperiodontics.com



Case Studies

Subepithelial Connective Tissue Graft:

Patient presented with generalized gingival recession and generalized mucogingival defects. The maxillary arch was treated from tooth #3 to #14 in one surgical appointment. The patient's own connective tissue was used in this case, but donor tissue can be used in certain instances. There is no other technique for root coverage that has the amount of research and long-term data as this technique. As you can see, an excellent esthetic and functional result was achieved.



Services

Offered By Eastern Oklahoma Periodontics

- Implant placement
 - Cosmetic periodontics
 - Hard and soft tissue grafting
 - Treatment of periodontal disease
- which includes implant site preparation*



Eastern Oklahoma Periodontics

6565 South Yale Ave. Ste. 1008
Tulsa, OK 74136